

Paraneoplastic sclerodermiform syndrome – case report

João Rovisco¹, Sara Serra¹, Pedro Abreu², Margarida Coutinho¹, Tânia Santiago¹, Luís Inês¹, José António Pereira da Silva¹

ACTA REUMATOL PORT. 2014;39:87-90

ABSTRACT

Occasionally, auto-immune diseases may emerge as paraneoplastic syndromes. This is especially recognized in the case of polymyositis/dermatomyositis, but it is an extremely rare event in systemic sclerosis (SSc). The authors report the case of a sixty-year-old woman who presented with Raynaud's phenomenon and rapidly progressing skin thickness of the forearms, hands and lower limbs. Patient evaluation revealed a colorectal carcinoma. The patient was referred to the oncology department. This concomitance of cancer and SSc with rapid progression of the latter, suggests that the scleroderma might have a paraneoplastic origin. Such an hypothesis deserves consideration in every case as early diagnosis may be decisive to control the progression of either disease.

Keywords: Paraneoplastic syndrome; Systemic sclerosis; cancer.

INTRODUCTION

Systemic sclerosis (SSc) is a connective tissue disorder characterized by cutaneous sclerosis with visceral involvement. Its etiology is unclear, but some genetic factors have been implicated in disease susceptibility and pattern of clinical manifestations. The pathogenesis, which is still obscure, includes vascular, inflammatory and fibrotic processes.

The association of SSc with cancer seems to be much stronger than mere coincidence. The prevalence of cancer in patients with systemic sclerosis has been estimated between 3 and 11%. Lung cancer is the most fre-

quently observed in these patients¹. On average the neoplastic manifestation occurs 13 years after the diagnosis. The simultaneous onset of cancer and SSc, suggesting a possible paraneoplastic origin to the connective tissue disease, is rarely seen. Even though the literature reports several cases, there are no classification criteria for paraneoplastic scleroderma, accessing its incidence hard to estimate. The current paradigm would require that the scleroderma manifestations regress after suitable treatment for the underlying cancer, in order to consider the case as paraneoplastic. This has been ascertained/determined in a number of published reports²⁻⁴.

CASE REPORT

A sixty-year-old woman was admitted to the Rheumatology Department for clinical investigation of bilateral Raynaud's phenomenon and skin changes that had begun a year before. In the last four months she developed not only persistent and diffuse hand edema and progressive thickening of the skin of the fingers, hands, forearms and face but also sicca syndrome. During the systematic enquiry, the patient described episodes of bloody diarrhea, and the loss of six kilograms in weight within that period of time.

The patient had hypertension and hypothyroidism, and had been previously submitted to hysterectomy and bilateral anexectomy for ovarian cysts. During a colonoscopy performed five years before, a sigmoid colon adenomatous polyp was identified and removed.

The patient worked in a paper factory, had no contact with chemical products and denied smoking habits as well as alcohol or illicit drugs consumption. At the time of admission the patient was submitted to treatment with lisinopril, hydrochlorothiazide, levotiroxin, amitriptilin and oral iron.

The physical examination showed microstomy, skin

1. Centro Hospitalar e Universitário de Coimbra
2. Unidade Local de Saúde de Castelo Branco, EPE

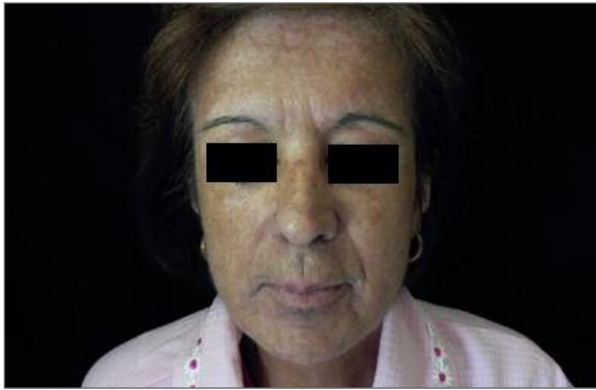

FIGURE 1. Skin thickness of face, microstomy

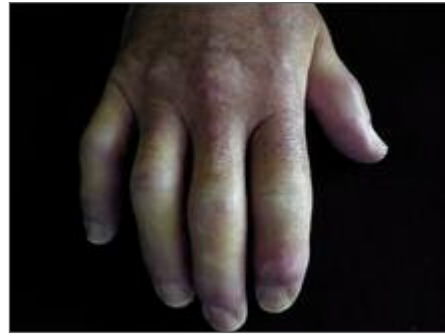

FIGURE 2. Sclerodactyly, PIP oligoarthritis

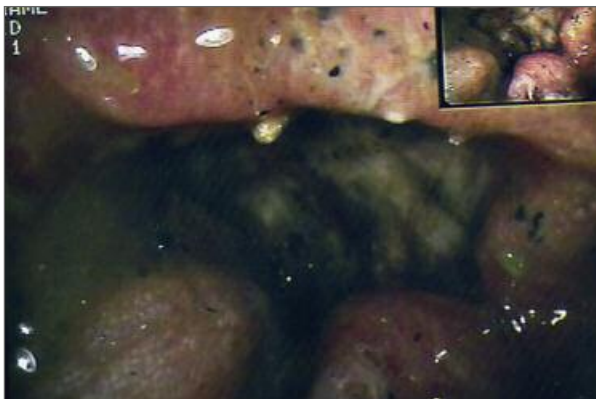

FIGURE 3. Colonoscopy showing a tumoral mass

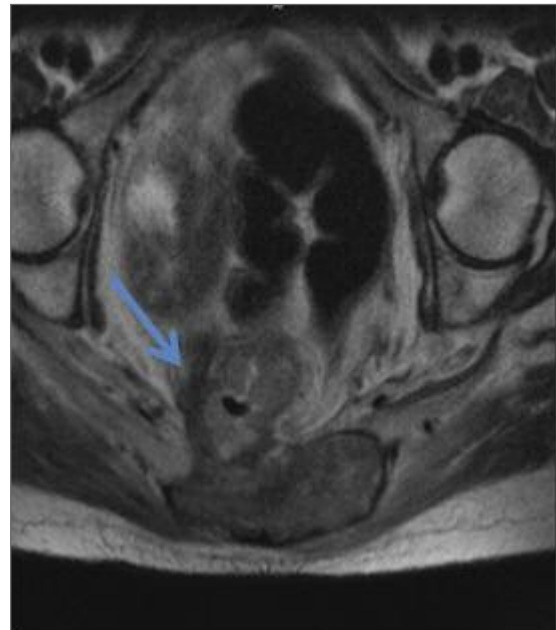


FIGURE 4. MRI of pelvic region revealing the invasion of the sacrum and the coccyx by tumoral tissue

thickening of the upper and lower limbs (distal to the elbows and knees) and sclerodactyly, with trophic scar lesions in the fingers and moderate oligoarthritis in the proximal interphalangeal (PIP) joints of both hands (Figs. 1 and 2). The modified Rodnan skin thickness score was 20 (range 0-51). The chest skin was normal. There were no other remarkable findings on clinical examination.

Laboratory tests revealed moderate microcytic normochromic anemia (Hb10.3 g/dl), elevated erythrocyte sedimentation rate (45 mm/hour), positive anti-nuclear antibodies (ANA) (>1/640) and positive anti-Scl 70. Tumor markers were negative, except CA 19.9, which was slightly elevated (78 U/L). The biochemistry blood analysis, urinalysis, protein immuno-electrophoresis and thyroid hormone levels were normal.

Chest X-ray and lung function tests were normal. The nailfold capillaroscopy revealed enlarged capillaries and avascular areas. The patient underwent colonoscopy, which revealed an irregular ulcerated lesion,

10 cm from the anal margin, compatible with a neoplasm (Fig. 3). The computerized axial tomography scan of the thorax, abdomen and pelvis and the magnetic resonance imaging (MRI) of the pelvis confirmed the neoplasm diagnosis and revealed the infiltration of the sacrum and the coccyx. A metastatic nodule in the iliac bone, and lymphadenopathies in relation to the neoplastic tissue were also revealed (Fig 4). The neoplasm was staged as pT4 N1 M1. The patient was referred to the Oncology Department and was treated with radiotherapy. Unfortunately, the treatment was unsuccessful and the patient died within 4 months, precluding additional assessment of SSc and the associated antibody profile.

DISCUSSION

We present a clinical case showing a rapidly progressing SSc with a concomitant colorectal carcinoma.

Skin thickening can be found in several diseases such as systemic sclerosis, eosinophilia-myalgia syndrome, eosinophilic fasciitis, graft vs host disease, mycosis fungoides, nephrogenic systemic fibrosis, primary biliary fibrosis, primary pulmonary hypertension, reflex sympathetic dystrophy, scleredema, scleromyxedema, endocrine disorders and amyloidosis. It can also develop after exposure to chemotherapeutic agents and organic solvents or in patients with an underlying cancer. All these conditions, except for SSc and paraneoplastic sclerodermiform syndrome, were excluded from this clinical case.

It is known that auto-immune diseases can be triggered by tumor development, commonly referred as paraneoplastic syndromes. These can emerge after the tumor or metastases onset, simultaneously to the neoplasm diagnosis or they can be the cancer's early manifestation^{5,6}.

The underlying mechanisms may include the release of active mediators by the cancer cells, such as the transforming growth factor beta, resulting in scleroderma skin changes⁷. Another hypothesis is based in an auto-immune reaction triggered by the expression by tumor cell of antigens that cross-react with those implicated in the primary auto-immune disease. Other authors argue that the cancer and the rheumatic condition are a consequence of similar exogenous stimuli, such as a viral infection or drug administration⁸.

Polymyositis/dermatomyositis is the most reported rheumatic paraneoplastic syndrome. Other commonly referred associations include vasculitis, polyarthritis and hypertrophic osteoarthropathy⁵. SSc is rarely described as a paraneoplastic syndrome, with only a few reports in the literature. The associated neoplasms in these reports include not only breast^{9,10}, lung¹¹, ovary, oral cavity and pharynx cancer but also non-Hodgkin lymphomas^{12,13}. The association with colorectal carcinoma is not well documented. Orphanos et al¹⁴ described the case of a 56-year-old man, diagnosed with an adenocarcinoma of the rectum, who developed telangiectasias and small cheek skin lesions 3 months after the surgery. The patient sought medical help 5 years after surgery and, at the time, presented skin thickening, distal to the metacarpophalangeal joints, atrophic skin lesions of the face and dyspnea. Laboratory tests showed him to be positive for both anti-nuclear

antibodies (ANA) and anti-Scl-70. Although scleroderma started after surgical removal of the tumor, a paraneoplastic origin was suggested, since further investigation revealed metastatic disease in the lung.

Two other reports^{2,3} described scleroderma manifestations and elevated titers of ANA within a few months after the first symptoms of the colon adenocarcinoma. These patients underwent surgery for neoplasm resection, with subsequent resolution of the scleroderma lesions, thus supporting their paraneoplastic origin.

The current classification criteria do not allow distinction between SSc and the paraneoplastic sclerodermiform syndrome. The diagnosis is obtained on a clinical basis, including the age of onset, the timely association with cancer of symptoms onset and response to treatment. Paraneoplastic rheumatic syndromes may coincide or follow the diagnosis of primary malignancy, but could precede the onset of cancer by two years⁵. The development of the rheumatic disease is frequently closely related with the development of cancer^{5,15}. In fact, there is a symptom recovery and a decrease of the antibody levels as the tumor tissue disappears or reduces^{2,3}.

Paraneoplastic sclerodermiform syndrome is firstly associated with a later age of onset, a refractory and unilateral Raynaud's phenomenon, and a poor response to conventional treatment²⁻⁵. Secondly it is also connected with a good response to the treatment of the underlying tumour with amelioration of symptoms and decrease or disappearance of antibody titers, which are the key to distinguish paraneoplastic from primary auto-immune SSc^{6,16}.

The presence of antibodies, typical of rheumatic diseases, is frequent in the paraneoplastic condition and delays the diagnosis of the occult neoplasm¹⁷.

In a study¹⁸ that assessed the prevalence of ANA in 94 patients, with paraneoplastic syndrome of solid tumors, forty patients presented arthritis and twenty four exhibited Raynaud phenomenon. The study showed that 22.3% of the patients were ANA positive. The anti-extractable nuclear antigen (ENA) antibodies were even more frequent, existing in 27.7% of the patients. Until recently, there were no studies reporting the association between the antibody profile and a potential underlying cancer in scleroderma. Shah and colleagues¹⁹ showed a close temporal relationship between the cancer onset in scleroderma and the presence of anti-RNA polymerase I/III antibodies. The average duration of disease at cancer diagnosis was -1.2 years (range - 2 to 1.3 years) and the mean time lapse since Ray-

naud onset was 0.25 years. In 66,6% of these patients, cancer diagnosis closely preceded scleroderma onset. However, the number of patients was small (23 patients recruited, 6 with anti-RNA polymerase I/III antibodies).

Regrettably, the short time of survival did not allow us to assess the possible effect of radiotherapy on the scleroderma and the antibody profile.

The possibility that a threatening disease such as SSc could be resolved or improved by the treatment of a triggering neoplasm lead us to publish this case, hoping to stimulate the consideration of the paraneoplastic hypothesis in patients who have SSc. Moreover, this report emphasizes that classification criteria are necessary to estimate the real prevalence of paraneoplastic scleroderma.

The clinical procedures in these patients should have in mind the most frequent neoplasms associated with this disease. In patients' follow-up, the surveillance of signs, symptoms and immunological profile may help to fully elucidate the diagnosis and assess the disease progression.

CORRESPONDENCE TO

João Pedro Lopes Rovisco
Rua das Romeiras, nº 37, 2ºesq
3030-471 Coimbra, Portugal
E-mail: ocisvor@gmail.com

REFERENCES

1. Abu-Shakra M, Guillemin F, Lee P. Cancer in systemic sclerosis. *Arthritis Rheum* 1993;36:46-54
2. Joliot AY, Vittori F, Allard C and Levrat R: Sclerodermie en plaques symptomatique d'un cancer du rectum. *Nouv Presse Med* 8: 703, 1979.
3. Lefevre C, Tousignant J, Chartier S and Demers D: Colonic adenocarcinoma and scleroderma. *Ann Dermatol Venereol*:120(4): 293-295, 1993.
4. Hounkpati A, Marie I, Paillotin D, Muir J.-F, Cuvelier A: Syndrome Sclerodermiforme paranéoplasique. *Rev Mal Resp* 2010;27: 251-256
5. Fam AG. Paraneoplastic rheumatic syndrome. *Best Pract Res Clin Rheumatol* 2000;14:515-533
6. András C, Csilki Z, Ponyi A, Illés A, Dankó K. Paraneoplastic rheumatic syndromes. *Rheumatol Int*:2006;26:376-382
7. Fujii T, Mimori T, Kimura N, Satoh S, Hirakata M. Pseudoscleroderma associated with transforming growth factor beta1-producing advanced gastric carcinoma: comment on the article by Varga. *Arthritis Rheum* 2003; 48: 1766-1767; (author reply 1767-8).
8. Racanelli V, Prete M, Minoia C, Favoino E, Perosa F. Rheumatic disorders as paraneoplastic syndromes. *Autoimmun Rev* 2008;7:352-358.
9. Lee P, Alderdice C, Wilkinson S et al. Malignancy in progressive systemic sclerosis – Association with breast carcinoma? *J Rheumatol* 1983;10:655-656.
10. Lu TY, Hill CL, Pontifex EK and Roberts-Thomson PJ: Breast cancer and systemic sclerosis: a clinical description of 21 patients in a population-based cohort study. *Rheumatol Int* 2008;28(9):895-899.
11. Peters-Golden M, Wise RA, Hochberg M et al. Incidence of lung cancer in systemic sclerosis. *J Rheumatol* 1985;12:1136-1139.
12. Derk CT, Rasheed M, Spiegel JR, Jimenez SA. Increased incidence of carcinoma of the tongue in patients with systemic sclerosis. *J Rheumatol* 2005; 32: 637-641.
13. Hill CL, Nguyen AM, Roder D, Roberts-Thomson P. Risk of cancer in patients with scleroderma: a population based cohort study. *Ann Rheum Dis* 2003; 62: 728-731
14. Orphanos G, Ardavanis A, Charalambous P, Stavrakakis J, Rigatos G. Systemic Sclerosis Associated with Rectal Cancer. Case Report and a Brief Review of the Literature. *in vivo* 22: 825-830 (2008)
15. Wenzel J. Scleroderma and malignancy: Mechanisms of interrelationship. *Eur J Dermatol* 2002;12:296-300
16. Leandro MJ, Isenberg DA. Rheumatic diseases and malignancy – is there an association? *Scand J Rheumatol* 2001;30:185-188.
17. Abu-Shakra M, Buskila D, Ehrenfeld M, Conrad K, Shoenfeld Y (2001) Cancer and autoimmunity: autoimmune and rheumatic features in patients with malignancies. *Ann Rheum Dis* 60:433-441
18. Ruginé R, Dadonienė J, Alcknavi ius E et al. Prevalence of paraneoplastic syndromes and their antibody profile among patients with solid tumors. *Clin Rheumatol* 2011;30:373-380
19. Sham A, Rosen A, Hummers L, Wigley F, Casciola-Rosen L. Close Temporal Relationship Between Onset of Cancer and Scleroderma With RNA Polymerase I/III Antibodies. *Arthritis Rheum* 2010;62:2787-2795.