

IMAGES IN RHEUMATOLOGY

# Gastrointestinal bleeding – an atypical presentation of granulomatosis with polyangiitis

Moniz AC<sup>1</sup>, Teixeira de Almeida M<sup>2</sup>, Pereira B<sup>3</sup>, Ponte C<sup>4,5</sup>, Valido A<sup>6</sup>

## INTRODUCTION

Granulomatosis with polyangiitis (GPA) is an anti-neutrophil cytoplasmic antibody (ANCA)-associated vasculitis characterized by necrotizing granulomatous inflammation involving the small- and medium-sized vessels, leading to vascular destruction<sup>1</sup>. It is typically associated with proteinase 3 (PR3)-ANCA and most commonly affects the ear, nose, throat, lower respiratory tract and kidneys. GI involvement is uncommon in GPA, estimated to occur in only 0-7% of patients<sup>2</sup>. It particularly reveals during the initial stages of the disease, most frequently in the first 2 years<sup>3,4</sup>.

## CASE REPORT

We describe a case of a 60-year-old man presenting at the emergency department complaining of bloody diarrhoea for one week. He also referred otalgia and ear

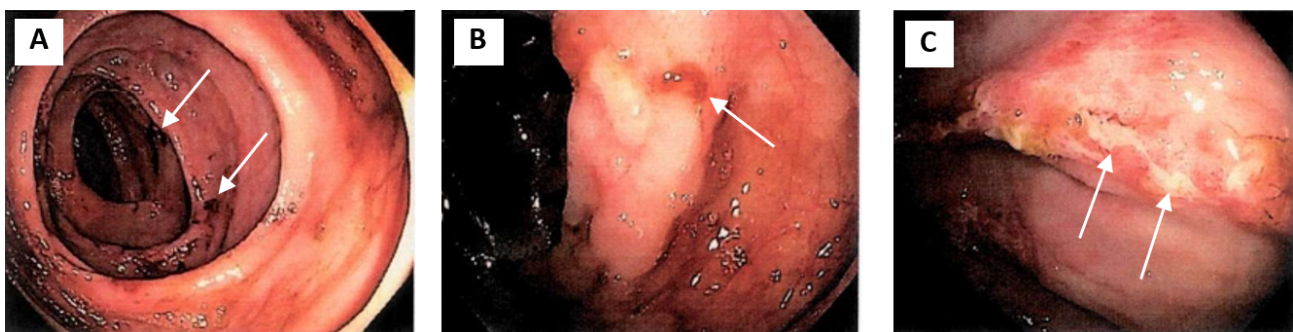
fullness, for which he had already started amoxicillin/clavulanate without improvement. He denied fever, weight loss or night sweats. On physical examination, he was sweaty, hypertensive (blood pressure of 152/100 mmHg) and slightly tachycardic (heart rate of 101 bpm), but afebrile and normoxemic. The abdomen presented hyperactive bowel sounds, but palpation was unremarkable. Laboratory studies showed haemoglobin of 12.8 g/dL, leucocytes of 7100 cells/mm<sup>3</sup> without eosinophilia, creatinine of 1.3 mg/dL, erythrocyte sedimentation rate (ESR) of 83 mm/hr and C-reactive protein (CRP) of 12.89 mg/dL. Head computerized tomography (CT) revealed otitis with mastoiditis. The patient was admitted for intravenous (IV) antibiotic therapy with piperacillin/tazobactam. After five days, the bloody diarrhoea progressed to heavy haematochezia, resulting in severe anaemia (haemoglobin of 7.6 g/dL) requiring multiple blood transfusions. Colonoscopy showed ulcers in the right colon (Figure 1) with biopsies revealing inflammatory cell infiltrates, fibrosis and a granuloma. Alongside, he also developed acute kidney injury (serum creatinine of 2.3mg/dL, microscopic haematuria and 24h-protein of 1g), increasing inflammatory parameters (ESR of 103 mm/h and CRP of 20.14 mg/dL) and oral ulcerations (Figure 2). A full infectious panel was employed, including mycobacteria, which came back negative. He did not start any treatment while completing the study. At day 26 of admission, he experienced new-onset dyspnea, cough with bloody sputum and hypoxemia. CT scan revealed massive alveolar haemorrhage (Figure 3). He started IV methylprednisolone (1 g/day for three days), followed by oral prednisolone (1 mg/kg/day), and IV im-

<sup>1</sup>Rheumatology, Unidade Local de Saúde de Lisboa Ocidental, Lisboa, Portugal; <sup>2</sup>Infectious Diseases, Unidade Local de Saúde de Lisboa Ocidental, Lisboa, Portugal; <sup>3</sup>Gastroenterology, Unidade Local de Saúde do Litoral Alentejano, Santiago do Cacém, Portugal; <sup>4</sup>Rheumatology, Unidade Local de Saúde de Santa Maria, Centro Académico de Medicina de Lisboa (CAML), Lisboa, Portugal; <sup>5</sup>Rheumatology Research Unit, Instituto de Medicina Molecular, Faculdade de Medicina, Universidade de Lisboa, CAML, Lisboa, Portugal; <sup>6</sup>Rheumatology, Unidade Local de Saúde do Litoral Alentejano, Santiago do Cacém, Portugal.

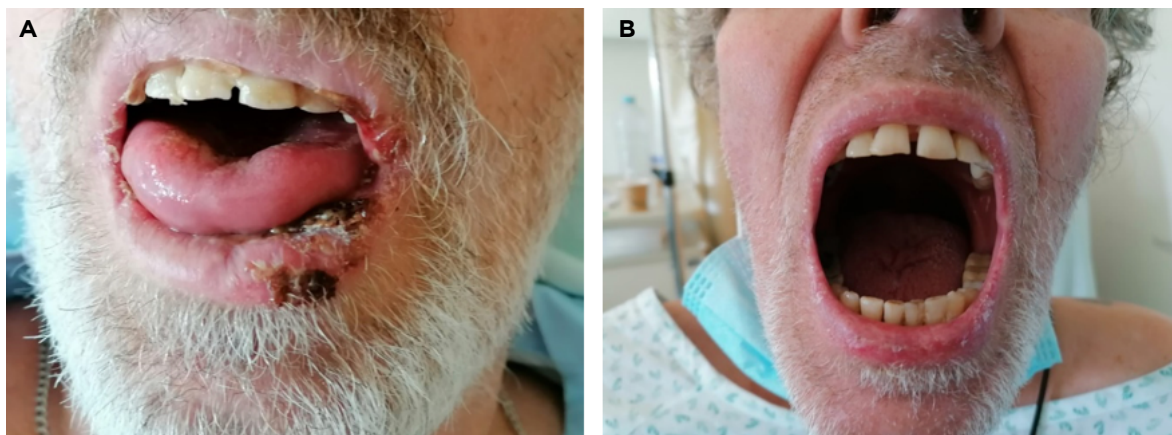
Submitted: 04/06/2024

Accepted: 21/07/2024

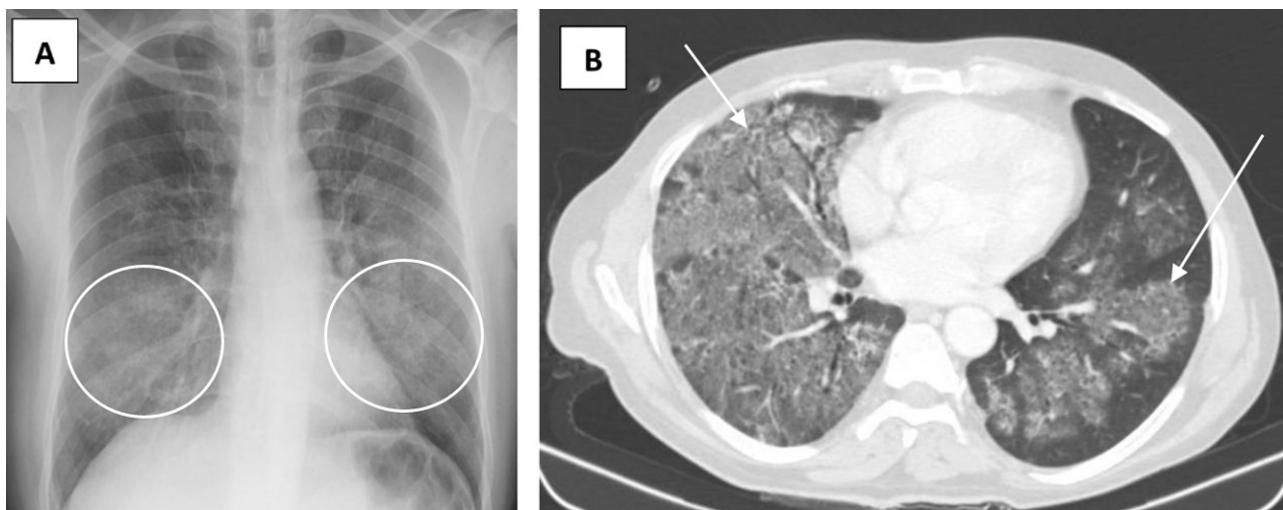
Correspondence to Ana Catarina Moniz  
E-mail: [acteixeira@ulslo.min-saude.pt](mailto:acteixeira@ulslo.min-saude.pt)



**Figure 1.** Colonoscopy images reveal fecal and hematic content on the colonic walls (A, indicated by arrows) and ulcerations with normal surrounding mucosa, showing no signs of active bleeding (B and C, indicated by arrows).



**Figure 2.** Oral ulcerations before (A) and after glucocorticoid therapy (B).



**Figure 3.** Posterior-anterior chest radiography (A) shows bilateral diffuse alveolar opacities in the mid zones (indicated by circles). The CT scan (B) reveals acute bilateral ground glass opacities with smooth interlobular septal thickening, creating a crazy-paving pattern (indicated by arrows). In the patient's clinical context, these findings suggest diffuse alveolar hemorrhage.

munoglobulin (2g/kg). Immunology confirmed a positive PR3-ANCA (167 UA/mL) with negative antinuclear antibodies. The diagnosis of GPA was established and the patient was started on IV cyclophosphamide (CYCLOPS protocol). Disease remission was achieved with improvement of anaemia, renal function, respiratory and GI symptoms. The patient was discharged after 34 days and remained in remission maintenance therapy with methotrexate 15 mg/week and prednisolone 7.5 mg/day in a tapering scheme, with no registered relapses after two years of follow-up.

## CONCLUSION

Although uncommon, GI manifestations can be potentially life threatening and debilitating. The most com-

mon manifestation is abdominal pain (32%), followed by nausea (17%) and oral mucosal ulcerations (17%). Bloody diarrhoea and GI bleeding are comparatively rare, reported in only 3% and 6% of patients, respectively<sup>5</sup>. Our case embodies an exceptional presentation of GPA and timely diagnosis contributes to preventing catastrophic outcomes. Nonetheless, the patient responded well to immunosuppressive therapy with glucocorticoids and cyclophosphamide.

## REFERENCES

1. Austin, K. et al. ANCA Associated Vasculitis Subtypes: Recent Insights and Future Perspectives. *J Inflamm Res* 2022; 15; 2567-2582. <https://doi.org/10.2147/JIR.S284768>
2. Jennette, J. C. et al. 2012 Revised International Chapel Hill Consensus Conference Nomenclature of Vasculitides. *Arthritis Rheum* 2013;65;1-11. <https://doi.org/10.1002/art.37715>
3. Storesund, B., Gran, J. T. & Koldingsnes, W. Severe Intestinal

- Involvement in Wegener's Granulomatosis: Report of Two Cases and Review of the Literature. *British Journal of Rheumatology* 1998;vol. 37. <https://doi.org/10.1093/rheumatology/37.4.387>
4. Masiak, A., Zdrojewski, L., Zdrojewski, Z., Bułło-Piontecka, B. & Rutkowski, B. Gastrointestinal tract involvement in granulomatosis with polyangiitis. *Gastroenterology Review* 2016;4:270-275. <https://doi.org/10.5114/pg.2016.57887>
  5. Grygiel-Górniak, B., Limphaibool, N., Perkowska, K. & Puszczewicz, M. Clinical manifestations of granulomatosis with polyangiitis: key considerations and major features. *Postgrad Med* 2018;130:581-596. <https://doi.org/10.1080/00325481.2018.1503920>