


CASE BASED REVIEWS

Clinical and persistent remission in anti-HMGCR immune-mediated necrotizing myopathy to a single cycle of rituximab – a case-based review

Silva SP^{1,2} , Eugénio G^{1,2}, Pinto M³, Barcelos A^{1,2,4,5}

ABSTRACT

Anti-HMGCR myopathy is an increasingly recognized immune-mediated necrotizing myopathy. However, there are currently no evidence-based treatments available, so case reports and clinical experience are used to guide current management. We report a case of a 49-year-old man, treated with atorvastatin, who presented to the emergency department with progressive proximal muscle weakness. Anti-HMGCR antibodies were detected, and muscle biopsy revealed necrotizing myopathy. Initially, therapy with high-dose glucocorticoids and methotrexate was started, but 12 weeks later, the patient developed clinical deterioration with dysphagia. Then, he was successfully treated with one cycle of rituximab along with physical therapy. The use of rituximab in immune-mediated necrotizing myopathy has been heterogeneously described in the literature but mostly in case reports. The European Neuromuscular Centre working group recommends the use of rituximab in refractory cases. However, some studies highlight the importance of early and aggressive treatment for this disease. Clinical prospective studies are necessary to make proper evidence-based recommendations.

Keywords: Rituximab; Histopathology; Myositis and muscle disease; Muscle; Biological therapies.

INTRODUCTION

Immune-mediated necrotizing myopathies (IMNM) are a subtype of idiopathic inflammatory myopathies (IIM), characterized by proximal muscle weakness, elevated creatine kinase (CK), and a muscle biopsy with necrosis and little inflammatory infiltrates¹. This rare but increasingly recognized myositis has three different subtypes that have been identified based on the presence of specific antibodies²: anti-3-hydroxy-3-methylglutaryl coenzyme A reductase (anti-HMGCR), anti-signal recognition particle (anti-SRP), and seronegative myopathy¹. These conditions differ clinically and in their pathophysiology. Most cases of anti-HMGCR myopathy have been related to statin use, but other drug exposures and malignancy have also been implicated³. Since there are currently no evidence-based treatments for this rare condition,

case reports and clinical experience are used to guide current management⁴. The European Neuromuscular Centre (ENMC) working group recommends starting treatments with glucocorticoids and an alternative agent such as methotrexate (MTX)⁴. In contrast to other myopathies, IMNM have a worse prognosis, are more likely to relapse and require multiple combination therapies⁴. The use of rituximab (RTX) is limited, and varying responses are described in the literature. We report a case of anti-HMGCR myopathy successfully treated with one cycle of RTX, along with a literature review to further support its use in this disorder.

CASE REPORT

A 49-year-old Caucasian male patient, autonomous for daily life activities, presented to the emergency department with a 2-week history of myalgia, progressive proximal upper and lower limbs weakness, and a weight loss of 15 kg. He denied the occurrence of fever, anorexia, dyspnea, arthralgia, skin lesions, dysphagia, oral ulcers, photosensitivity, xerostomia, xerophthalmia, Raynaud's phenomenon, or any other symptoms. He was being treated with 800 mg of metformin and 20 mg of atorvastatin daily for type 2 diabetes mellitus and dyslipidemia, respectively, and had a history of active smoking (34 pack years). Physical examina-

¹ Rheumatology Department, Centro Hospitalar do Baixo Vouga, Aveiro, Portugal; ² Centro Académico Clínico Egas Moniz Health Alliance, Aveiro, Portugal; ³ Neuropathology Unit, Neurosciences Department, Centro Hospitalar e Universitário de Santo António, Porto, Portugal; ⁴ EpiDoC Unit, CEDOC, NOVA Medical School, Universidade Nova de Lisboa, Lisboa, Portugal; ⁵ NOVA National School of Public Health, Public Health Research Centre, Comprehensive Health Research Center (CHRC), Universidade NOVA de Lisboa, Lisboa, Portugal.

Submitted: 20/03/2024

Accepted: 01/05/2024

Correspondence to: Susana P Silva
E-mail: susanna_ps@hotmail.com

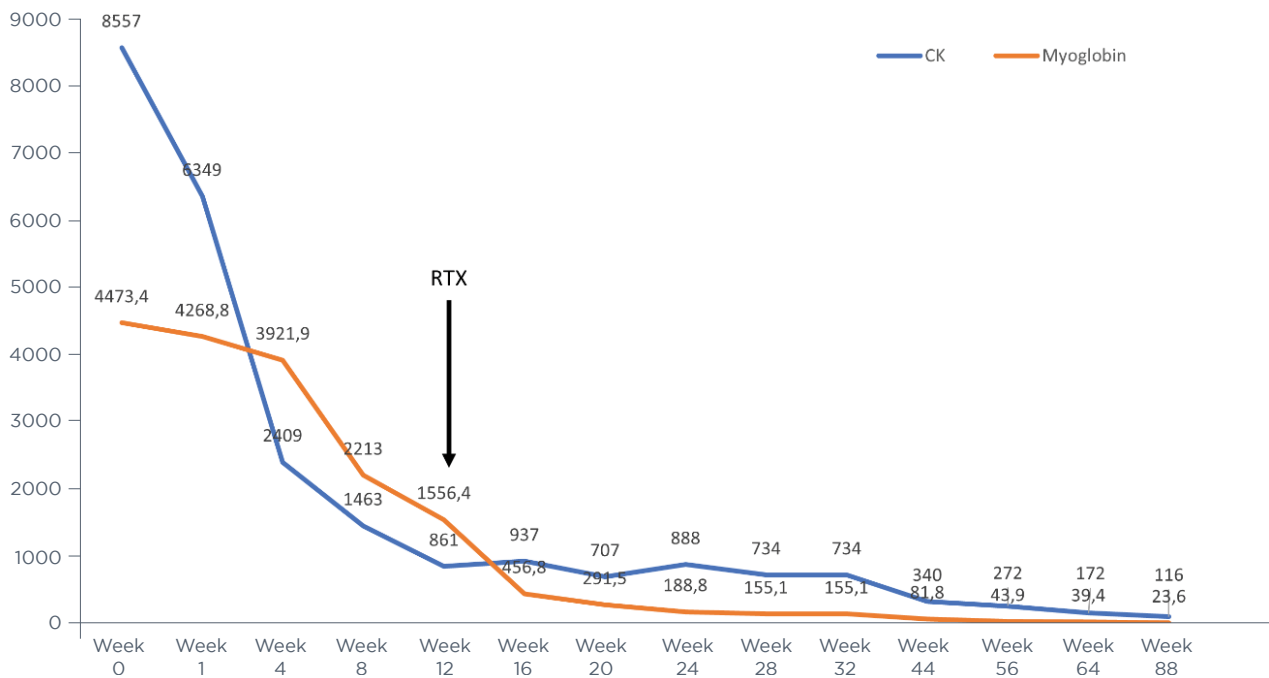


Figure 1. CK and myoglobin levels evolution.

tion revealed a grade of 4/5 on the Medical Research Council (MRC) Scale for Muscle Strength in bilateral shoulder abduction and hip flexion. Cervical flexion and distal strength were normal. There were no cutaneous features nor joint swelling, and cardiorespiratory and abdominal examinations were normal. Laboratory studies demonstrated increased CK levels of 9730 U/L (normal <145) (Fig. 1), myoglobin of 4529.8 ng/mL (normal <110), lactate dehydrogenase (LDH) of 999 U/L (normal value <246), aspartate transaminase of 432 U/L (normal <40), alanine transaminase of 657 U/L (normal <46) and aldolase 133.1 U/L (normal <32.0). Acute phase reactants, electrolytes, creatinine, thyroid function, glycated hemoglobin, and urinalysis were normal. He was hospitalized for statin-induced rhabdomyolysis, but despite stopping the statins and vigorous hydration, his symptoms worsened, and his CK levels did not improve. Human immunodeficiency, hepatitis B, and C virus screening were negative. Chest, abdominal, and pelvic computed tomography ruled out paraneoplastic myositis. The electromyography showed characteristics indicative of an active myopathic process with abnormal spontaneous activity. Right deltoid biopsy revealed myopathic changes, including moderate variation in the fiber size, numerous necrotic myofibers, myophagocytosis, and scattered regenerative fibers (Fig. 2 - A and B). Major histocompatibility complex (MHC-1) immunostaining on the frozen tissue showed weak sarcollemal staining (Fig. 2-C). A pery-

misial and perivascular inflammatory infiltrate was also observed. Immunohistochemistry revealed a small inflammatory infiltrate composed of both CD4+ helper T cells and CD8+ cytotoxic T cells and macrophages (Fig. 2-D). Anti-HMGCR antibodies were positive, with a titer >200 UA (normal <20). Oral prednisolone dose of 1 mg/kg/day and MTX 15 mg/week were started at week 8. However, during his follow-up, clinical deterioration was seen, with a manual muscle testing (MMT) 8 score of 77/150 and the development of dysphagia for solids and liquids. Due to a national shortage of intravenous immunoglobulin (IVIg) during the COVID-19 pandemic, one cycle of RTX 1000mg (2 doses two weeks apart) was administered at week 12, and the patient started a rigorous physical plan at a rehabilitation center. Eight weeks later, a physical examination revealed improvement in muscular strength, with a MMT8 of 123/150, and laboratory values (CK 707 U/L; myoglobin of 291.5 ng/mL). Prednisolone was gradually reduced until it was stopped throughout the follow-up period, and MTX was continued. Two years later, he is functionally recovered (MMT8 150/150) with normalization of CK and myoglobin and withdrawal of all immunosuppression.

DISCUSSION

We describe a case of a male patient with anti-HMGCR

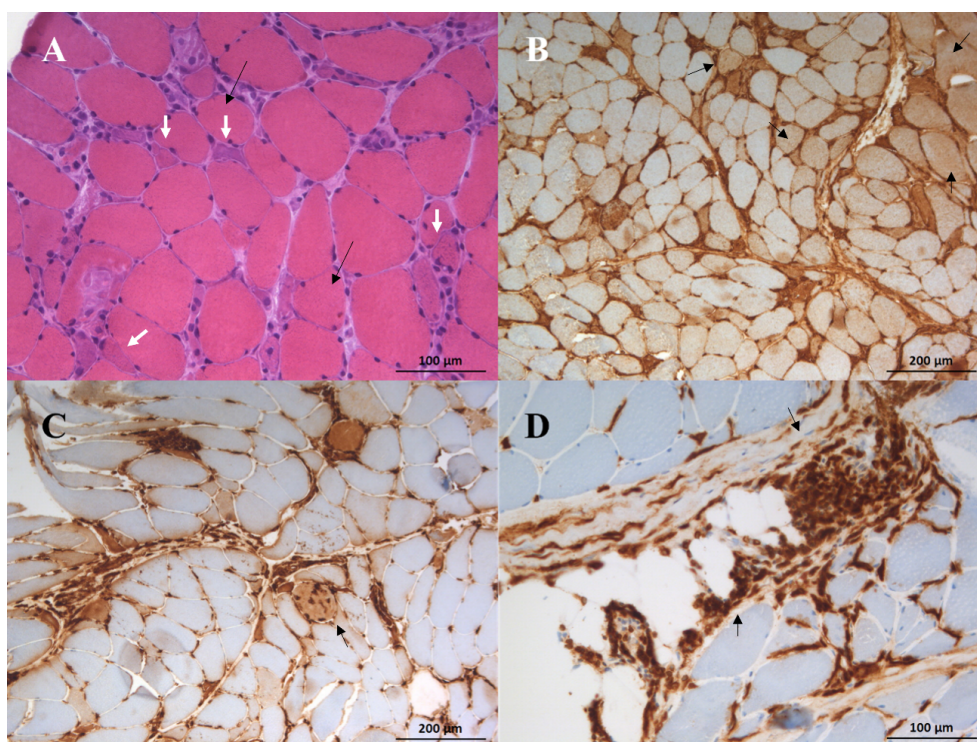


Figure 2. A - Deltoid muscle biopsy exhibiting numerous necrotic and regenerating fibers over a diffusely myopathic pattern (H&E stain). B - MHC-I immunohistochemistry showing scattered positive fibers. C - Numerous macrophages were found, particularly associated with myophagocytosis of necrotic fibers (CD68 immunohistochemistry). D - The perimysial inflammatory infiltrate was mainly composed of T cells (CD3 immunohistochemistry) with no predominance of CD4 over CD8 lymphocytes.

IMNM with a refractory course, successfully treated with one cycle of RTX, in addition to glucocorticoids and MTX. Despite the growing awareness of IMNM, evidence-based guidelines for its treatment are still needed.

We performed a systematic review of the literature of MEDLINE/Pubmed and EMBASE, according to PRISMA guidelines, up to June 2023, without any language restrictions. We used the combination of the terms “anti-3-hydroxy-3-methylglutaryl-CoA reductase”, OR “necrotizing myopathy”, AND “rituximab”. The database search identified a total of 131 publications, out of which we excluded 19 duplicates, 39 papers that were not related to anti-HMGCR myopathy, 35 articles that were not case reports or case series, 14 cases not treated with RTX, 2 pediatric cases and 11 cases after reading the full text. We included 16 papers that reported a total of 19 cases of anti-HMGCR myopathy treated with RTX, which are presented in Table I.

The first reported cases of IMNM with anti-HMGCR antibodies were published by Ramanathan *et al.*⁵. Of 2 patients treated with RTX, a 60-year-old man failed to respond but subsequently improved with IVIG as a maintenance treatment⁵. The other case had an incomplete response to RTX⁵. Boppana *et al.* presented a case of a 46-year-old man with neuromuscular respira-

tory failure who was successfully treated with RTX and IVIG⁶. However, it was difficult to determine whether the sustained remission was due to RTX or maintenance therapy with IVIG, making it hard to attribute the clinical improvement to RTX⁶. Waheed *et al.* described a favorable response in a statin-naïve paraneoplastic anti-HMGCR myopathy to a single cycle of RTX in an 81-year-old man with lung cancer⁷. In a study carried out by Landon-Cardinal *et al.*, the authors concluded that longer and refractory disease could be responsible for the absence of response, and anti-HMGCR antibodies were not correlated with clinical outcomes⁸. Later, four case reports showed good responses to RTX treatment^{9,10}. Other cases with favorable responses to RTX treatment are also described in the literature^{11,12,13,14}. Two cases described a good response to RTX in anti-HMGCR myopathy with a more chronic presentation, mimicking limb-girdle muscular dystrophy^{15,16}.

The current standard of care for patients with IMNM is glucocorticoids⁴. However, many individuals are resistant to steroid-only therapy, requiring the use of a combination of immunosuppressants¹⁷. As steroid-sparing medications, MTX, azathioprine, and mycophenolate mofetil can be used. However, there are currently no clinical trials to advise the selection of immunosuppres-

TABLE I. Cases of anti-HMGCR myopathy treated with RTX.

Author, year	Age/Sex	Previous statin exposure	Anti-HMGCR antibodies	Baseline CK (U/L)	Treatment (other than RTX)	RTX regime	Improvement with RTX
Ramanathan et al, 2015 [5]	60/M	Yes	Positive	16200	GC, AZA, MTX, IVIG	NA	No (IVIG maintenance)
	77/M	Yes	Positive	4300	GC, MTX, PE, IVIG, CYC	NA	Partial (IVIG maintenance)
Young et al, 2015 [9]	58/F	Yes	Positive	6000	GC, AZA, MMF	2 cycles (1g day 1 and 15) 6 months apart	Complete
Sweidan et al, 2017 [22]	70/M	Yes	Positive	12 300	GC, MTX	1g for 3 doses	Partial (died of ventilator-associated Pneumonia)
Zhang et al, 2019 [10]	60/F	Yes	Positive	11003	GC, MTX, CsA, IVIG	Ongoing 6/6 months*	Complete (with IVIG and MTX)
	68/F	Yes	Positive	3900	GC, MTX, IVIG	8/8 weeks*	Complete (with IVIG and MTX)
	62/M	Yes	Positive	5000	GC, MTX, IVIG, CsA, PE	NA*	Complete (with IVIG and MTX)
Waheed et al, 2019 [7]	81/M	No	Positive	7217	GC, MTX	1 cycle (1g day 1 and 15)	Complete (with MTX)
Landon-Cardinal et al, 2019 [8]	25/M	No	Positive	10391	GC, PE, CYC, IVIG, AZA	1 cycle (1g day 1 and 15) and re-perfused 1g	Complete (with MTX)
	64/M	No	Positive	7137	GC, PE, MTX, IVIG	every 6 months at the discretion of the treating physician	Complete (with MTX)
	36/F	No	Positive	5985	GC, MTX, AZA, IVIG		Failure (with AZA and IVIG)
	40/F	No	Positive	13537	GC, MTX		
Thomas et al, 2020 [11]	63/F	Yes	Positive	6000	GC, MTX	2 cycles (1g day 1 and 15) 6 months apart	Complete
Barrons et al, 2020 [14]	54/M	Yes	Positive	13618	GC, IVIG	1g day 1 and 20	Complete (IVIG)
Idiculla et al, 2020 [15]	44/F	No	Positive	491	IVIG	375 mg/m ² once weekly for a total of six doses	Partial
Gupta et al, 2021 [12]	61/F	Yes	Positive	15000	GC, AZA	3 cycles (1g day 1 and 15) every 3 months	Complete
Boppana et al, 2021 [6]	46/M	Yes	Positive	22000	GC, MTX, IVIG	NA	Complete (with IVIG)
Lorenzo-Villalba et al, 2021 [16]	27/M	No	Positive	6918	GC, MTX, IVIG	1 cycle (1g day 1 and 15)	Partial (IVIG and MTX)
Yeo et al, 2022 [13]	55/F	Yes	Positive	6981	GC, MTX, IVIG, AZA	1 st cycle: 500 mg 2 weeks apart 2 nd cycle: 1g 3 weeks apart	Partial (AZA, MTX and IVIG)

anti-HMGCR - anti-3-hydroxy-3-methylglutaryl coenzyme A reductase, AZA – azathioprine, CK – creatine kinase, CsA – cyclosporine, CYC - cyclophosphamide, F- female, GC – glucocorticoids, IVIG - intravenous immunoglobulin, M- male, MTX - methotrexate, MMF - mycophenolate mofetil, PE – plasma exchange, RTX – rituximab, NA - not available.

*Lymphoma induction protocol: 375 mg/m² once weekly 4x, followed by a maintenance dose of 375 mg/m² every month, with further dose frequency reduction tailored to individual patients.

sive drugs in IMNM⁴. Treatment guidelines suggest the combination of glucocorticoids and MTX as first-line therapy^{4, 18}. In patients with anti-HMGCR IMNM, the addition of IVIG instead of or in addition to MTX is also recommended^{4, 18}. RTX is reserved for refractory cases, but the ENMC supports its early use in anti-SRP myopathy^{4, 18}. RTX is a B-cell depletion therapy that prevents

the maturation of B-cells into plasma cells^{8,19}. While the exact pathophysiology of anti-HMGCR IMNM is still unknown, it is believed that anti-HMGCR antibodies play a role in its development, enhancing the possible role of RTX in its treatment^{1,20}. Although RTX has been used in IMNM, there is currently a lack of controlled studies evaluating its effectiveness in this regard. Exist-

ing literature suggests that RTX has a positive impact on clinical and laboratory outcomes^{5,8,22}, but there have also been cases with a partial or absent response^{5,21,23}. IMNM may require early aggressive treatment to prevent muscle atrophy and fatty replacement²⁴. Also, unlike other myopathies, IMNM have a worse prognosis, are more likely to relapse and require multiple combination therapies, which can contribute to progressive damage²⁴. Most cases reported in the literature are from patients who are refractory or resistant to high-dose glucocorticoids and conventional immunosuppressive drugs. After a long period, there may have been irreversible damage and significant fatty replacement of muscle, with little improvement with RTX²⁵. Also, in a recent retrospective study based on 55 cases of anti-HMGCR myopathy, delay in treatment initiation was independently associated with lower odds of successful maintenance with immunosuppressant monotherapy²⁶. Given the worse prognosis of anti-HMGCR IMNM compared to other IIM, early and aggressive treatment can be an important factor in improving patients' prognosis²⁶. In our case, prompt treatment with RTX may have been one of the factors contributing to his favorable response. Thus, RTX, like IVIG, can be a viable option for early treatment of anti-HMGCR myopathy.

In summary, we identified 19 cases in the literature, most of whom responded to various RTX regimens (43.3% achieved a complete response and 33.3% a partial response). All patients had previously been refractory to multiple immunosuppressive agents, which could account for the limited improvements. Therefore, RTX may be a useful alternative for treating anti-HMGCR myopathy, not just in cases where other treatments have failed but also as a first-line therapy. Our review presents the limitation that we cannot definitively attribute clinical improvement solely to RTX, as some patients were treated with multiple concomitant medications. Additionally, the literature describes multiple treatment plans with variable doses and numbers of infusions. Information regarding the best evidence-based treatment recommendations is lacking. Thereby, we emphasize the need for clinical trials to evaluate the effect of RTX in anti-HMGCR IMNM, thus leading to better management of this condition.

REFERENCES

- Allenbach Y, Benveniste O, Stenzel W, Boyer O. Immune-mediated necrotizing myopathy: clinical features and pathogenesis. *Nat Rev Rheumatol*. 2020;16(12):689-701. <https://doi.org/10.1038/s41584-020-00515-9>
- Christopher-Stine L, Casciola-Rosen LA, Hong G, Chung T, Corse AM, Mammen AL. A novel autoantibody recognizing 200-kd and 100-kd proteins is associated with an immune-mediated necrotizing myopathy. *Arthritis Rheum*. 2010;62(9):2757-2766. <https://doi.org/10.1002/art.27572>
- Aggarwal R, Moghadam-Kia S, Lacomis D, Malik A, Qi Z, Koontz D, et al. Anti-hydroxy-3-methylglutaryl-coenzyme A reductase (anti-HMGCR) antibody in necrotizing myopathy: treatment outcomes, cancer risk, and role of autoantibody level. *Scand J Rheumatol*. 2020;49(5):405-411. <https://doi.org/10.1080/03009742.2019.1672782>
- Allenbach Y, Mammen AL, Benveniste O, Stenzel W, Immune-Mediated Necrotizing Myopathies Working Group. 224th ENMC International Workshop: Clinico-sero-pathological classification of immune-mediated necrotizing myopathies Zandvoort, The Netherlands, 14-16 October 2016. *Neuromuscul Disord*. 2018;28(1):87-99. <https://doi.org/10.1016/j.nmd.2017.09.016>
- Ramanathan S, Langguth D, Hardy TA, Garg N, Bundell C, Rojana-Udomsart A, et al. Clinical course and treatment of anti-HMGCR antibody-associated necrotizing autoimmune myopathy. *Neurol Neuroimmunol Neuroinflamm*. 2015;2(3):e96. <https://doi.org/10.1212/NXI.0000000000000096>
- Boppana SH, Syed HA, Antwi-Amoabeng D, Reddy P, Gullapalli N. Atorvastatin-Induced Necrotizing Myopathy and its Response to Combination Therapy. *Cureus*. 2021;13(1):e12957. <https://doi.org/10.7759/cureus.12957>
- Waheed W, Jones C, Gentchos G, DeWitt J, Tandan R. Favorable Response in Statin-Naive Paraneoplastic Anti-HMGCR Antibody-Associated Myopathy to Single Dose of Rituximab and Persistent Remission With Management of Underlying Lung Cancer. *J Clin Neuromuscul Dis*. 2019;21(1):14-24. <https://doi.org/10.1097/CND.0000000000000248>
- Landon-Cardinal O, Allenbach Y, Soulages A, et al. Rituximab in the Treatment of Refractory Anti-HMGCR Immune-mediated Necrotizing Myopathy. *J Rheumatol*. 2019;46(6):623-627. <https://doi.org/10.3899/jrheum.171495>
- Young JB, Ghobrial II. Autoimmune statin-induced myopathy: a case report. *J Community Hosp Intern Med Perspect*. 2015;5(4):28374.
- Zhang W, Prince HM, Reardon K. Statin-induced anti-HMGCR antibody-related immune-mediated necrotizing myositis achieving complete remission with rituximab. *BMJ Case Rep*. 2019;12(11):e232406. <https://doi.org/10.1136/bcr-2019-232406>
- Thomas R, Yeoh SA, Berkeley R, Woods A, Stevens M, Marino S, et al. Initial seronegative immune-mediated necrotizing myopathy with subsequent anti-HMGCR antibody development and response to rituximab: case report. *BMC Rheumatol*. 2020;4:29. <https://doi.org/10.1186/s41927-020-00128-5>
- Gupta S, Rakhra A, Thallapally V, Nahas J. Rituximab use for refractory anti-HMGCR immune-mediated necrotizing myopathy: A case report. *Intractable Rare Dis Res*. 2021;10(2):122-125. <https://doi.org/10.5582/irdr.2020.03144>
- Yeo CH, Yaakub A, Wang MCL, et al. Refractory Statin-Induced Immune-Mediated Necrotizing Myositis: Challenges and Perils in Its Management. *Cureus*. 2022;14(5):e24778. <https://doi.org/10.7759/cureus.24778>
- Barrons R, Woods JA, Humphries R. Statin Associated Autoimmune Myonecrosis: Case Report With Delayed Onset and Treatment Challenges. *J Pharm Pract*. 2022;35(1):129-134. <https://doi.org/10.1177/0897190020958223>
- Idiculla PS, Govindarajan R. Anti-HMGCR myopathy mimicking limb-girdle muscular dystrophy and the response to rituximab. *Clin Neurol Neurosurg*. 2020;194:105871. <https://doi.org/10.1016/j.clineuro.2020.105871>
- Lorenzo-Villalba N, Andrès E, Meyer A. Chronic Onset Form of Anti-HMG-CoA Reductase Myopathy. *Eur J Case Rep Intern Med*. 2021;8(7):002672. https://doi.org/10.12890/2021_002672

17. Nazir S, Lohani S, Tachamo N, Poudel D, Donato A. Statin-Associated Autoimmune Myopathy: A Systematic Review of 100 Cases. *J Clin Rheumatol*. 2017;23(3):149-154. <https://doi.org/10.1097/RHU.0000000000000497>
18. Oldroyd AGS, Lilleker JB, Amin T, et al. British Society for Rheumatology guideline on management of paediatric, adolescent and adult patients with idiopathic inflammatory myopathy. *Rheumatology (Oxford)*. 2022;61(5):1760-1768. <https://doi.org/10.1093/rheumatology/keac115>
19. Hiepe F, Dörner T, Hauser AE, Hoyer BF, Mei H, Radbruch A. Long-lived autoreactive plasma cells drive persistent autoimmune inflammation. *Nat Rev Rheumatol*. 2011;7(3):170-178. <https://doi.org/10.1038/nrrheum.2011.1>
20. Arouche-Delaperche L, Allenbach Y, Amelin D, et al. Pathogenic role of anti-signal recognition protein and anti-3-Hydroxy-3-methylglutaryl-CoA reductase antibodies in necrotizing myopathies: Myofiber atrophy and impairment of muscle regeneration in necrotizing autoimmune myopathies. *Ann Neurol*. 2017;81(4):538-548. <https://doi.org/10.1002/ana.24902>
21. Rademacher JG, Glaubitz S, Zechel S, Oettler M, Tampe B, Schmidt J, et al. Treatment and outcomes in anti-HMG-CoA reductase-associated immune-mediated necrotizing myopathy. Comparative analysis of a single-centre cohort and published data. *Clin Exp Rheumatol*. 2022;40(2):320-328. <https://doi.org/10.55563/clinexprheumatol/2ao5ze>
22. Sweidan AJ, Leung A, Kaiser CJ, Strube SJ, Dokukin AN, Roman-sky S, et al. A Case of Statin-Associated Autoimmune Myopathy. *Clin Med Insights Case Rep*. 2017;10:1179547616688231. <https://doi.org/10.1177/1179547616688231>
23. Mohammed AGA, Gcelu A, Moosajee F, Botha S, Kalla AA. Immune Mediated Necrotizing Myopathy: Where do we Stand?. *Curr Rheumatol Rev*. 2019;15(1):23-26. <https://doi.org/10.2174/1573397114666180406101850>
24. Weeding E, Tiniakou E. Therapeutic management of immune-mediated necrotizing myositis. *Curr Treatm Opt Rheumatol*. 2021;7(2):150-160. <https://doi.org/10.1007/s40674-021-00174-1>
25. McGrath ER, Doughty CT, Amato AA. Autoimmune Myopathies: Updates on Evaluation and Treatment. *Neurotherapeutics*. 2018;15(4):976-994. <https://doi.org/10.1007/s13311-018-00676-2>
26. Meyer A, Troyanov Y, Drouin J, et al. Statin-induced anti-HMGCR myopathy: successful therapeutic strategies for corticosteroid-free remission in 55 patients. *Arthritis Res Ther*. 2020;22(1):5. <https://doi.org/10.1186/s13075-019-2093-6>