

IMAGES IN RHEUMATOLOGY

Musculoskeletal embolization – endovascular treatment of adhesive capsulitis: first case reported in Portugal

Marinho Lopes P¹ , Cavalheiro F¹, Gonçalves R², Sousa F¹, Sousa P¹

INTRODUCTION

Adhesive capsulitis (AC), commonly known as frozen shoulder, is a debilitating condition characterized by pain and significant restriction of shoulder movement.

Various treatment modalities are commonly employed to address adhesive capsulitis, reflecting the multifaceted nature of this condition¹.

Recent angiographic studies have observed an abnormal neoangiogenesis around the glenohumeral joint described as “burning sign” or “tumor blush” that may explain, the origin of regional pain². Trans-arterial embolization (TAE) in patients with AC arises as a therapeutic alternative, with the aim of blocking arterial flow theoretically responsible for the inflammatory and fibrotic status^{3,4,5}.

CASE DESCRIPTION

A 50-year-old female presented with a history of progressively worsening pain and restricted range of motion in her left shoulder. Magnetic resonance imaging showed thickening of the joint capsule and synovium, confirming the diagnosis of AC. Patient had undergone multiple sessions of physiotherapy, aiming to improve shoulder mobility. However, the intensity of pain significantly limited her participation and progress during these sessions, despite analgesic management with opioids. The orthopedic surgeon referred to assess the feasibility of undertaking the recent technique of endovascular embolization.

She was informed about this technique, its recent nature, the results of published studies, as well as potential complications. Having decided to proceed with the procedure, she signed the informed consent, and the treatment was scheduled.

The procedure was performed in the angiography suite with radial access, utilizing a 5Fr introducer. The subclavian artery was catheterized with a 4Fr vascular catheter, followed by angiography (Figure 1). The thoraco-acromial artery was selectively catheterized using a 4Fr VER vascular catheter and superselectively with a 1.9Fr microcatheter (Asahi Tellus®) and a 0.016

¹ Serviço de Imagiologia, Unidade Local de Saúde Gaia - Espinho.
² Serviço de Ortopedia, Hospital de Ovar, Unidade Local de Saúde - Região de Aveiro.
Submitted: 19/03/2024
Accepted: 26/04/2024
Correspondence to: Pedro Marinho Lopes
E-mail: pedromarinholopes@hotmail.com

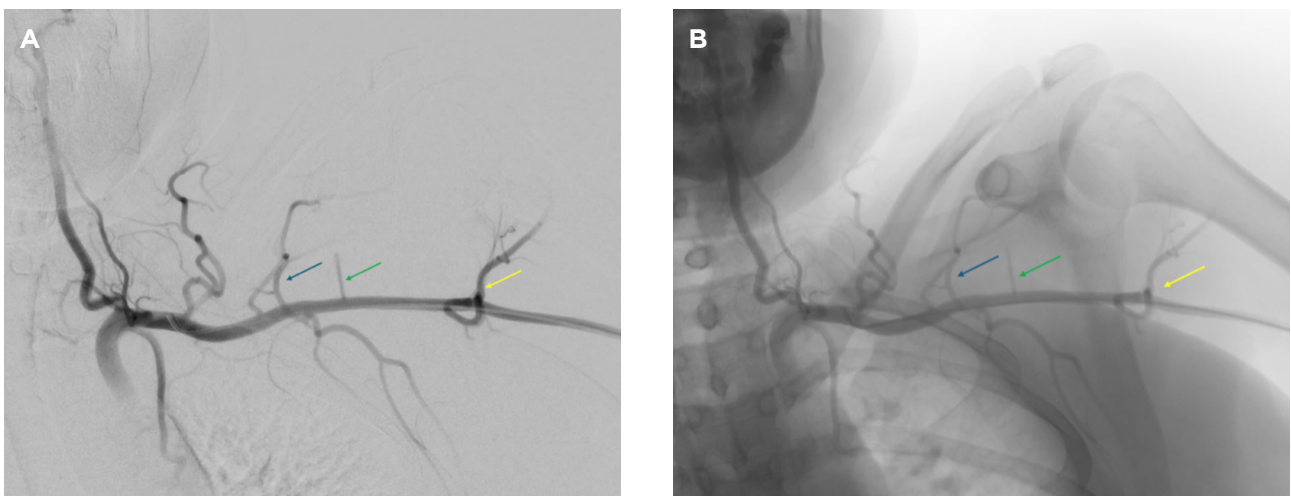


Figure 1. Subclavian angiography, highlighting the thoracoacromial artery (blue arrow), coracoid artery (green arrow), and circumflex scapular artery (yellow arrow) – a) with subtraction b) without subtraction

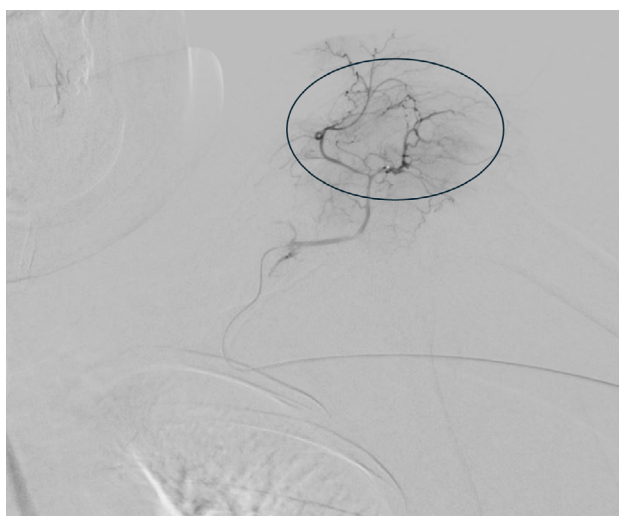


Figure 2. Superselective arteriography of the thoracoacromial artery identifying pathological areas in the coracoacromial region and rotator cuff interval (black ellipse).

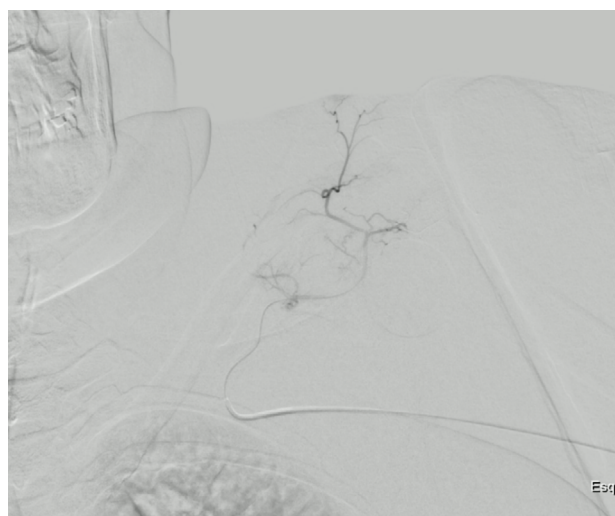


Figure 3. Post-embolization control - resolution of pathological areas with preservation of the remaining vascular heritage, including cutaneous branches.

microguide (Asahi Meister®). Pathological areas in the coraco-acromial region and the rotator cuff interval, described as vascular tortuosity, hyperemia and early venous drainage were identified (Figure 2) and selectively embolized using a temporary embolic agent (imipenem-cilastatin + contrast agent), until resolution of the pathological findings while preserving the surrounding vasculature (Figure 3). A control subclavian angiogram confirmed the resolution of the previously identified areas (Figure 4). Hemostasis of the vascular access was achieved using a radial compression device for 60 minutes. After this period, the patient was discharged from the recovery unit. No complications were recorded.

The patient did not require additional analgesic medication following the treatment. She resumed physical therapy one week after the endovascular treatment, successfully reengaging with significantly reduced pain. At the one-month follow-up, she reported a substantial reduction in pain and improved range of motion, although with slight functional limitation (VAS 4, Quick-Dash 28). At three-month, while still undergoing physical therapy, she reported an absence of pain and nearly normal mobility (VAS 0, Quick-Dash 7). At the six-month follow-up, she reported a pain-free status and normal mobility, participating in occasional physical therapy sessions only (VAS 0, Quick-Dash 0).

DISCUSSION

This innovative approach presents a promising alternative for patients with refractory adhesive capsulitis

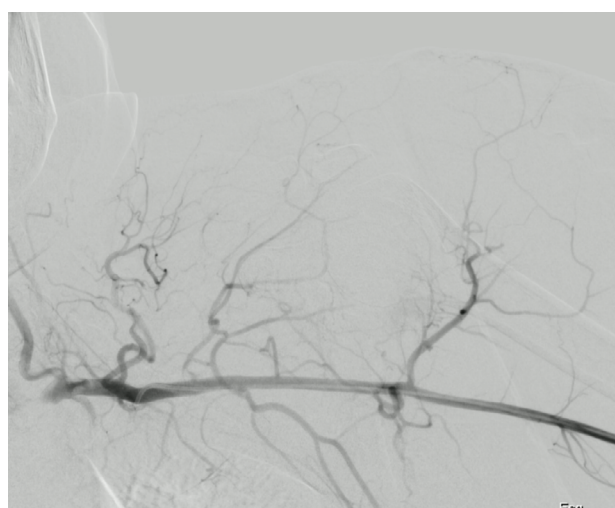


Figure 4. Subclavian angiogram post-embolization with resolution of the previously identified areas and preservation of the normal vascular structures identified in the initial angiography.

who fail to respond to conservative management. Further studies are warranted to validate the efficacy and safety of this technique in a larger patient population.

REFERENCE

1. D'Orsi GM, Gai Via A, Frizziero A, et al. Treatment of adhesive capsulitis: a review. *Muscles Ligaments Tendons J.* 2012; 10(2): 70-78.
2. Sasanuma H, Sugimoto H, Iijima Y, et al. Blood flow evaluation by dynamic magnetic resonance imaging of symptomatic rotator cuff tears and frozen shoulders. *J Shoulder Elbow Surg.* 2018; 27(12): e372-e379.
<https://doi.org/10.1016/j.jse.2018.05.042>

3. Aamre A, Rosa S. Therapeutic Arterial Embolization in Patients with Shoulder Adhesive Capsulitis: A Systematic Review. *J Orthopedics & Orthopedic Surg.* 2023;4(1):1-9. <https://doi.org/10.29245/2767-5130/2023/1.1170>
4. Okuno Y, Iwamoto W, Matsumura N, Oguro S, Yasumoto T, Kaneko T, et al. Clinical Outcomes of Transcatheter Arterial Embolization for Adhesive Capsulitis Resistant to Conservative Treatment. *J Vasc Interv Radiol.* 2017; 28:161-167. <https://doi.org/10.1016/j.jvir.2016.09.028>
5. Hindsø L, Riis R, Imich P, Petersen M, Nielsen M, Lønn L, Taudorf M. Current Status of Trans-Arterial Embolization in Pain Management of Musculoskeletal Inflammatory Conditions - An Evidence-Based Review. *Cardiovasc Intervent Radiol* 2021; 44:1699-1708. <https://doi.org/10.1007/s00270-021-02948-5>