

LETTERS TO THE EDITOR

# Varicella zoster virus mimicking giant cell arteritis

Martins-Martinho J<sup>1,2</sup>, Pintado Maury I<sup>3</sup>, Leal I<sup>4</sup>, Ponte C<sup>1,2</sup>

Giant cell arteritis (GCA) can lead to blindness in up to 20% of cases, most frequently due to arteritic anterior ischemic optic neuropathy (AION)<sup>1</sup>. Ultrasound of the temporal (TA) and axillary (AX) arteries is recommended as the first imaging modality in cases of suspected GCA, given its high diagnostic sensitivity and specificity<sup>2</sup>. However, when ultrasound results are negative, clinicians must consider alternative causes of anterior optic neuropathy, such as infectious or non-arteritic ischemic etiologies.

We report a case of an 81-year-old woman that presented to the Emergency Department with a 3-day painless and sudden vision loss in the right eye (RE). She reported having had an acute anterior uveitis in the six months prior, treated with topical steroids and cycloplegics for three months with resolution. She denied headaches, jaw claudication, weight loss and poly-

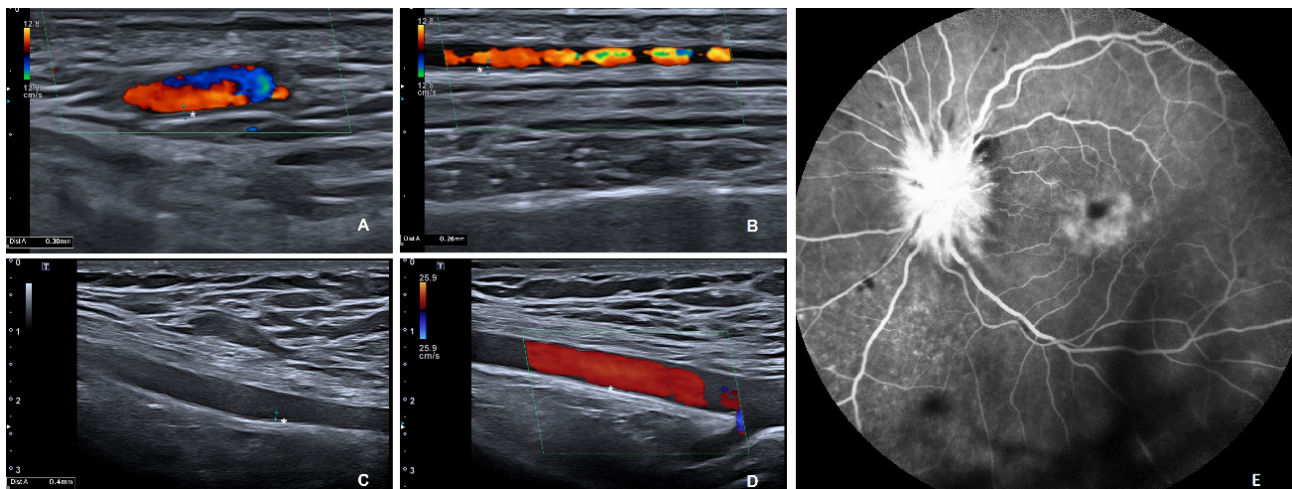
myalgia rheumatica symptoms. Her medical history included arterial hypertension, dyslipidemia and bilateral sequential cataract surgery at age 79. On ophthalmic examination, best corrected visual acuity (BCVA) was counting fingers at 50cm in the RE and 1.0 in the left eye (LE), with relative afferent pupillary defect in the RE. The intraocular pressure (IOP) was increased (26mmHg) in the RE and normal in the LE. Biomicroscopy of the RE showed mild cilioconjunctival hyperemia, mild corneal edema, and granulomatous keratic precipitates in the lower third of the cornea, with no cells in the anterior chamber. The RE fundus examination showed a pale edematous optic disc. These findings suggested AION overlapping with earlier anterior uveitis with papillitis. The remaining physical examination was unremarkable. The ESR was 64mm/hr and C-reactive protein was 1.1mg/dL. Orbits and cranial computed tomography showed ischemic microangiopathic leukoencephalopathy. The patient was started on 60mg/day of oral prednisolone, valacyclovir 1g tid, sulfamethoxazole and trimethoprim bid, and topical treatment for the RE with tropicamide, dexamethasone, and IOP-lowering drops. The TA and AX arteries ultrasound did not show a halo sign suggestive of GCA (Figure 1A-D). Thus, a TA biopsy was requested. Further inquiry revealed a recent episode of painful skin blisters that resolved spontaneously two months prior. Therefore, valacyclovir was increased to 2g tds and predniso-

<sup>1</sup>Centro Hospitalar Universitário Lisboa Norte, Rheumatology Department, Centro Académico de Medicina de Lisboa (CAML), EULAR Center of Excellence, Lisbon, Portugal; <sup>2</sup>Instituto de Medicina Molecular, Faculdade de Medicina, Universidade de Lisboa, CAML, Unidade de Investigação em Reumatologia, Lisbon, Portugal; <sup>3</sup>Centro Hospitalar Universitário Lisboa Norte, Infectious Diseases Department, Centro Académico de Medicina de Lisboa (CAML), Lisbon, Portugal; <sup>4</sup>Centro Hospitalar Universitário Lisboa Norte, Ophthalmology Department, Centro Académico de Medicina de Lisboa (CAML), Lisbon, Portugal

Submitted: 14/10/2023

Accepted: 01/01/2024

Correspondence to: Joana Martins Martinho  
E-mail: joanamartinsmartinho@gmail.com



**Figure 1.** Ultrasound of the right common superficial temporal artery (A), frontal branch of the left temporal artery (B) and right and left axillary arteries (C and D) in longitudinal view, showing a normal intima-media complex (\*). Fluorescein angiography of the left eye revealing contrast diffusion from the optic disc and macular region, suggestive of optic neuritis and macular edema, respectively, in the described clinical context (E).

lone tapered by 5mg every five days. Optic disc edema improved, but the BCVA remained at counting fingers. Serology results were positive for *herpes simplex virus* type 2 (IgM and IgG) and negative for HIV, toxoplasma, HBV, HCV and VDRL. IGRA and ANCA were negative and ACE was normal. Aqueous humor PCR analysis revealed positive DNA for *varicella-zoster virus* (VZV), while the TA biopsy was negative for GCA. The final diagnosis was VZV optic neuritis. Prophylaxis was maintained after treatment and discontinued after one year. Three months later, the patient relapsed with LE optic neuropathy (Figure 1E). At the time, ESR was 74mm/hr and CRP was 1.9 mg/dL. Repeat TA and AX ultrasound remained negative for GCA. The diagnosis of sequential VZV optic neuropathy was established and valacyclovir restarted *ad aeternum*.

In elderly patients with anterior optic neuropathy, while GCA is a primary concern, a thorough clinical evaluation is essential to exclude alternative conditions like VZV, syphilis, compressive lesions, ischemic non-arteritic etiologies, and sarcoidosis. VZV neuritis is very rare<sup>3</sup> and typically presents with decreased visual acuity, a relative afferent pupillary defect, and normal

or edematous optic nerve, which can progress to optic nerve atrophy. Neurological examination can unveil hypoesthesia in the region supplied by the ophthalmic branch of the trigeminal nerve and biomicroscopy may reveal anterior granulomatous uveitis with or without sectorial areas of iris atrophy.

This case also highlights the importance of ultrasound in assessing suspected GCA. Despite initial considerations, negative ultrasound prompted deeper investigation, facilitating the accurate diagnosis, preventing diagnostic delays and unnecessary glucocorticoid treatment.

## REFERENCES

1. González-Gay MA, García-Porrúa C, Llorca J, Hajeer AH, Brañas F, Dababneh A, et al. Visual Manifestations of Giant Cell Arteritis: Trends and Clinical Spectrum in 161 Patients: *Medicine* 2000;79:283-92. <https://doi.org/10.1097/00005792-200009000-00001>
2. DeJaco C, Ramiro S, Bond M, Bosch P, Ponte C, Mackie SL, et al. EULAR recommendations for the use of imaging in large vessel vasculitis in clinical practice: 2023 update. *Ann Rheum Dis* 2023;ard-2023-224543. <https://doi.org/10.1136/ard-2023-224543>
3. Marsh, R., Cooper, M. Ophthalmic herpes Zoster. *Eye* 7, 350-370 (1993). <https://doi.org/10.1038/eye.1993.74>