

IMAGES IN RHEUMATOLOGY

Parameniscal cyst: an important differential diagnosis in slow growing masses of the knee

Saraiva L¹, Saraiva AP¹, Coutinho M¹, Silva JAP¹

Meniscal cysts, located in the substance or the vicinity of the knee meniscus, are relatively uncommon, with a reported prevalence of 4-8%, among patients with confirmed or suspected knee lesions^{1,2}. Parameniscal cysts are small cystic lesions, near the meniscus, involving medial and lateral compartments at equal frequency^{3,4}. A study reported that 98% of parameniscal cysts occur in young patients due to extrusion of joint fluid through a meniscal tear, mostly horizontal^{3,5}. Frequently, parameniscal cysts are so small that patients do not notice them, being asymptomatic. However, they can grow and exceed 2 centimeters in diameter, causing pain and alarm due to the slow growing mass. Magnetic Resonance Imaging (MRI) is the gold standard for diagnosis. The differential diagnosis includes synovial cyst, baker cyst, ganglion cyst, bursitis, haematoma and neoplasms³. Treatment depends on symptoms and concomitant meniscus abnormalities. Open cystectomy with simultaneous meniscectomy or meniscal repair may be required^{3,5}.

Herein, we report a case of a 47-year-old male with idiopathic juvenile arthritis, in remission since 2013, who presented with a slow growing mass over the medial aspect of the right knee. The mass developed spontaneously, enlarging over the past year, without any previous trauma.

After 7 months of onset the patient had occasional discomfort at rest, not related with movements, relieved by non-steroidal anti-inflammatory drugs.

On physical examination, a firm immobile non-painful elastic mass was obvious on the medial aspect of right knee, with 3.5x3.5cm. without any other relevant findings (Figure 1A).

On ultrasound, an hypoechoic mass measuring 3.52x2.0cm was identified in the medial aspect of right knee, located externally to the medial meniscus, with slight internal septation, and no *power doppler* signal (Figure 1B).

MRI revealed a conspicuous cystic ovoid lesion, 3.05 cm in widest diameter, compatible with a parameniscal

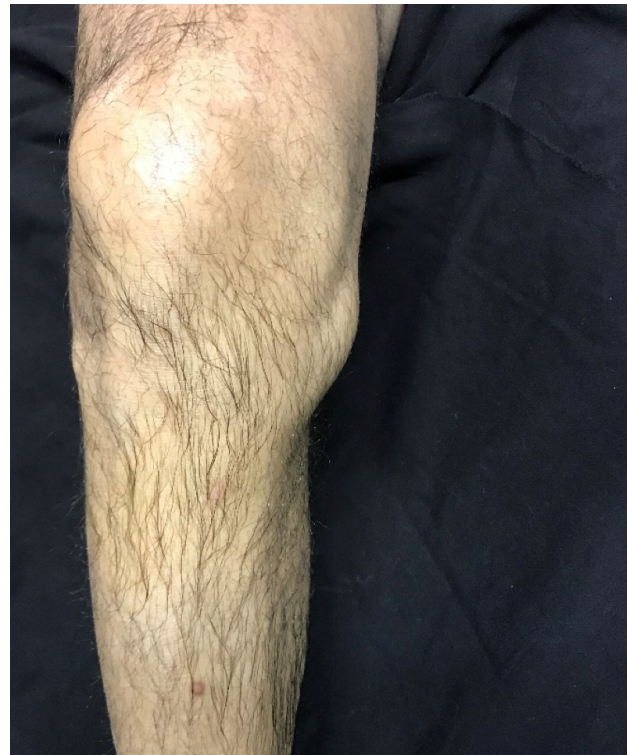

Figure 1A. Clinical appearance of the patient knee

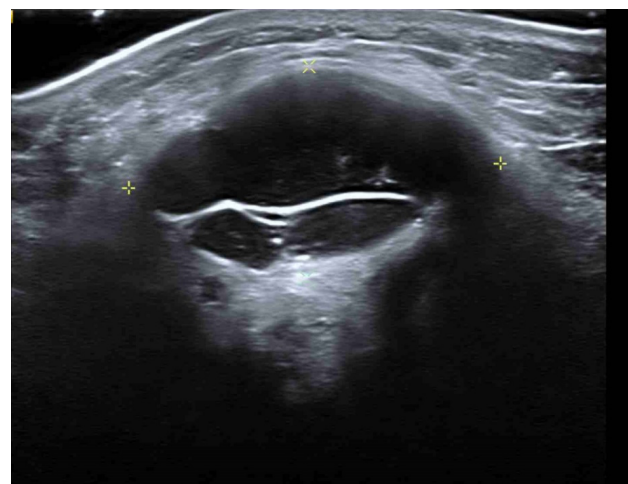


Figure 1B. Musculoskeletal ultrasound of the right knee (Siemens Acuson S-2000MT device, 18 MHz transducer, longitudinal view): presence of an hypoechoic lesion with well-defined borders and internal septation, in the internal side of the knee, medially located to internal meniscus, with 3.52 x 2.00 cm, suggestive of a cystic lesion.

¹ Reumatologia, Centro Hospitalar e Universitário de Coimbra.

Submitted: 16/11/2022

Accepted: 01/02/2023

Correspondence to: André Pinto Saraiva
E-mail: saraivaandre92@gmail.com

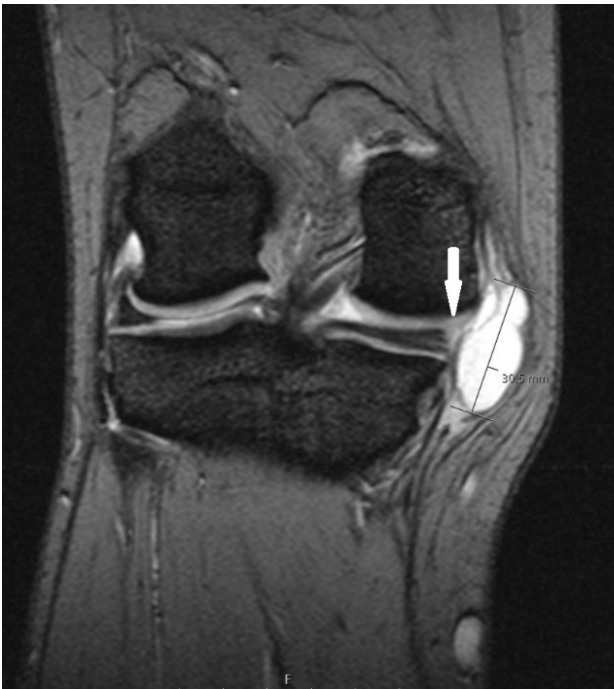

Figure 1C. A T2* Multi-GRE MRI sequence showing an ovoid cystic lesion with 3.05cm in the longest axis, compatible with a parameniscal cyst.

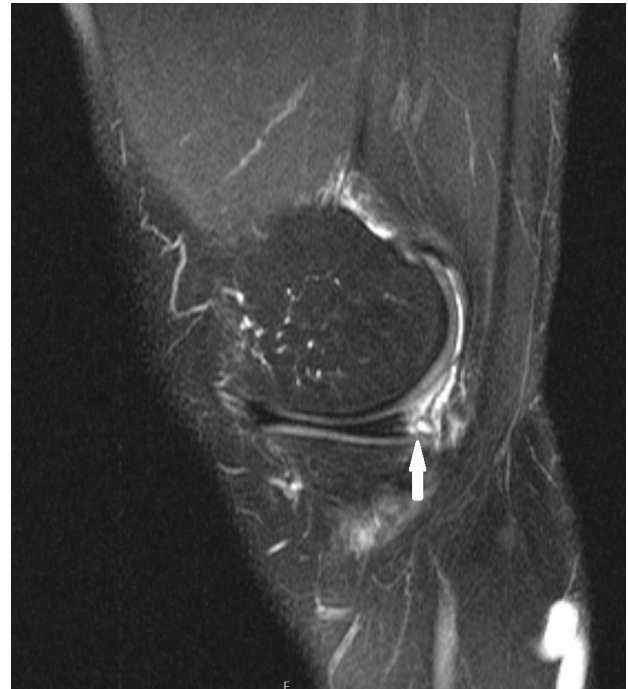

Figure 1D. A T2* Fat Suppression MRI sequence showing structural heterogeneity of the posterior horn of the internal meniscus, with a longitudinal fracture at this level, intercepting the inferior articular surface

cyst (Figure 1C). This was associated with structural heterogeneity of the posterior edge of the internal meniscus with a longitudinal fracture (white arrow) at this level, intercepting the inferior articular surface (Figure 1D). The patient had only mild pain and no disability. He declined surgery and conservative treatment was offered.

We present this case because to our knowledge this is the first case reported in patients with inflammatory rheumatic disease (IRD). Since the patient had been in remission for several years, the relationship between these two entities needs to be considered with caution. However, previous inflammatory changes might have predisposed to the occurrence of the meniscal tear, mainly because the patient had no previous trauma. Also, this parameniscal cyst was related to a longitudinal meniscal tear, representing an even more uncommon situation.

REFERENCES

1. Estrada M, Royero M, Arismendy D, Alzate J B. Cystic lesions of the knee. Pictorial review. *Colombian Journal of Radiology. Rev. Colomb. Radiol.* 2015; 26(1): 4121-32;
2. Anderson J J, Connor G F, Helms C A. New observations on meniscal cysts. *Skeletal Radiology.* 2010; 39(12): 1187-91;
3. Campbell S E, Sanders T G, Morrison W B. MR imaging of meniscal cysts: incidence, location, and clinical significance. *American Journal of Roentgenology.* 2001; 177(2):409-13.
4. Sivasubramanian H, Ee G, Srinivasaiah M G, Das De S, Sing AM. Not Always a Baker's Cyst' – an unusual presentation of a central voluminous postero-medial meniscal cyst. *Open Orthopaedics Journal.* 2012; 6:424–8.
5. Choi E H, Huang J, Bryk D, Bryk E. Giant medial parameniscal cyst in an osteoarthritic knee. *Orthopedics.* 2009; 32:e978–84.