

## Sustained drug-free remission and persistent hypogammaglobulinemia in a patient with rheumatoid arthritis three years after discontinuing Rituximab treatment

Krasselt M<sup>1</sup>, Baerwald C<sup>1</sup>, Seifert O<sup>1</sup>

ACTA REUMATOL PORT. 2021;46:191-192

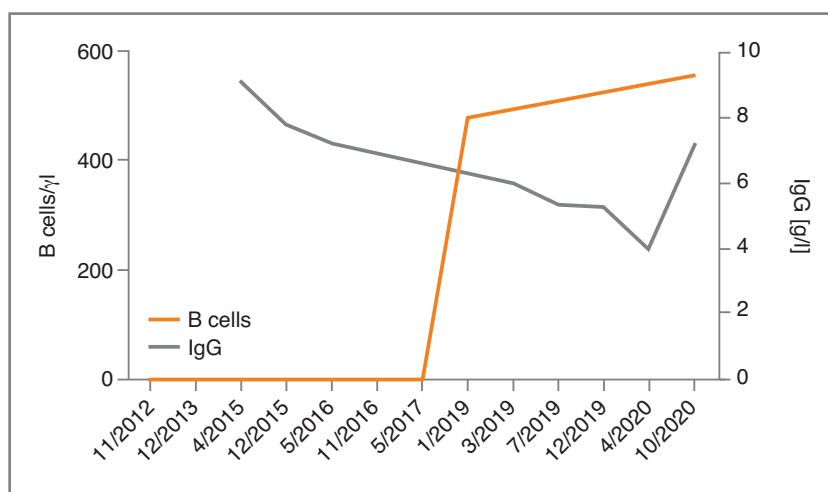
A 57-year-old woman has been under care for seronegative rheumatoid arthritis (RA) at our outpatient clinic since 1986. After receiving different types of DMARDs including methotrexate, adalimumab and etanercept without remission, a therapy with the B cell-depleting agent rituximab (RTX, 1 g twice every six months) was initiated in 2011. This therapy was not only well-tolerated but also led to disease remission. Prednisolone and MTX were stopped 2013. Hypogammaglobulinemia was detected in February 2017. Given the remission of the RA and increasingly occurring infections, RTX was applied last in August 2017. Although RTX was stopped, IgG decreased further (Figure 1). During this period, the patient suffered from different infectious diseases, particularly of the upper respiratory tract (e.g. laryngitis). In late 2019, a prolonged and refrac-

tory otitis media was diagnosed, which was not responding to three different antibiotic regimens. ENT colleagues suggested a surgical treatment. Accordingly, i.v.-supplementation of immunoglobulins was initiated in 2020. The continuous application led to the total absence of infections and surgical treatment of the otitis media was not necessary.

Remarkably, even though RTX was discontinued in 2017 and peripheral B cells were seemingly fully repopulated by early 2019 (Figure 1), no clinical activity of the RA was recognized to date. In October 2020, the patient is in sustained, drug-free clinical remission (DAS28-CRP: 1.18). Of importance, B cell subpopulations were measured for the first time in 2020 and showed increased counts of immature (8.1 %) and naïve (89.5 %) B cells at the almost total expense of memory cells (CD27<sup>+</sup> cells 1%).

Hypogammaglobulinemia under RTX therapy is

1. Rheumatologie, Universität Leipzig, Medizinische Fakultät



**FIGURE 1.** Total peripheral B cell count (CD19+) and Serum IgG levels [g/l] of the patient since initiation of the RTX therapy.

Note the discrepancy between B cell repopulation and further decreasing IgG. In October 2020, the seemingly fully recovered B cells consist of 1 % memory cells only (data not shown).

well-known<sup>1</sup>. Since the patient had no history of recurring infections before, RTX treatment was judged the most likely reason. In this context, the B cell count is of particular interest. Remarkably, kinetics of B cell repopulation differs in dependence of the underlying rheumatic disease: typically, B cell depletion is long-lasting in ANCA-associated vasculitis while it has been shown to be short-lasting in RA (B cell repopulation within one year in 10 vs. 93 %, respectively)<sup>2</sup>. Even if peripheral B cell counts are found to be normal after RTX discontinuation, humoral response might still be severely hampered<sup>3,4</sup>. It has been shown that receptor revision might be reduced after RTX treatment, meaning that the B cell compartment could consist of a reduced number of clones, lacking specific B cells<sup>5</sup>. A recent investigation even suggests that almost half the patients with persistent secondary hypogammaglobulinemia harbour genes associated with primary immunodeficiency disorders<sup>6</sup>.

The other interesting aspect of our report is the sustaining remission despite discontinuation of the RTX therapy for more than three years. As we know today, even low-dose regimens (1 g/6 months) can maintain response after reaching remission using conventional high dosing (1 g twice/6 months)<sup>7</sup>. Completers of the BeSt study achieved a drug-free remission in 15 % in year 7, regardless of their preceding medication<sup>8</sup>. In this context, drug-free sustained remission seems to be more likely in early than in established RA, probably by using the window of opportunity and reverting autoimmunity early<sup>9</sup>. While colleagues from France also reported a 9-year lasting remission in a patient with established RA after discontinuing RTX therapy, in contrast to our patient, B cells have remained undetectable during the whole follow-up<sup>10</sup>. Regarding our patient, we propose that, while peripheral immature and naïve B cells fully recovered, the almost total lack of memory B cells (CD27<sup>+</sup> 1%) contributes greatly to the achieved remission. Interestingly, such a “subset” of patients has been described by Barmettler et al in the context of prolonged hypogammaglobulinemia<sup>11</sup>.

#### CORRESPONDENCE TO

Marco Krasselt  
Rheumatologie, Universität Leipzig, Medizinische Fakultät  
E-mail: marco.krasselt@medizin.uni-leipzig.de

#### REFERENCES

1. Barmettler S, Ong MS, Farmer JR, Choi H, Walter J. Association of Immunoglobulin Levels, Infectious Risk, and Mortality With Rituximab and Hypogammaglobulinemia. *JAMA Netw Open* 2018;1:e184169.
2. Thiel J, Rizzi M, Engesser M, Dufner AK, Troilo A, Lorenzetti R, et al. B cell repopulation kinetics after rituximab treatment in ANCA-associated vasculitides compared to rheumatoid arthritis, and connective tissue diseases: a longitudinal observational study on 120 patients. *Arthritis Res Ther* 2017;19:101.
3. Steininger PA, Bobinger T, Dietrich W, Lee DH, Knott M, Bogdan C, et al. Two Cases of Severe Tick-Borne Encephalitis in Rituximab-Treated Patients in Germany: Implications for Diagnosis and Prevention. *Open Forum Infect Dis* 2017;4:ofx204.
4. Knight A, Pauksens K, Nordmark G, Kumlien E. Fatal outcome of tick-borne encephalitis in two patients with rheumatic disease treated with rituximab. *Rheumatology (Oxford)* 2017;56:855-856.
5. Palanichamy A, Muhammad K, Roll P, Kleinert S, Dorner T, Tony HP. Rituximab therapy leads to reduced imprints of receptor revision in immunoglobulin kappa and lambda light chains. *J Rheumatol* 2012;39:1130-1138.
6. Sogkas G, Dubrowskaja N, Adriawan IR, Anim M, Witte T, Schmidt RE, et al. High frequency of variants in genes associated with primary immunodeficiencies in patients with rheumatic diseases with secondary hypogammaglobulinaemia. *Ann Rheum Dis* 2020; Published Online First: 12 October 2020. doi:10.1136/annrheumdis-2020-218280.
7. Avgoustidis N, Flouri I, Adamichou C, Kabouraki E, Eskitzis A, Kyfonidou P, et al. FRI0244 Low dose of rituximab is effective for maintenance of clinical remission or low disease activity in patients with rheumatoid arthritis. *Annals of the Rheumatic Diseases* 2017;76:577.
8. van den Broek M, Lems WF, Allaart CF. BeSt practice: the success of early-targeted treatment in rheumatoid arthritis. *Clin Exp Rheumatol* 2012;30:S35-38.
9. Nagy G, van Vollenhoven RF. Sustained biologic-free and drug-free remission in rheumatoid arthritis, where are we now? *Arthritis Res Ther* 2015;17:181.
10. Coutant F, Rouzaire P, Soubrier M. An unexpected response to rituximab in a patient with rheumatoid arthritis. *Rheumatology (Oxford)* 2018;57:580-582.
11. Barmettler S, Price C. Continuing IgG replacement therapy for hypogammaglobulinemia after rituximab--for how long? *J Allergy Clin Immunol* 2015;136:1407-1409.