

Misleading symptoms of hereditary angioedema type II mimicking familial mediterranean fever

Barešić M¹, Karanović B¹, Coen Herak D², Kozmar A², Anić B¹

ACTA REUMATOL PORT. 2020;45:143-146

ABSTRACT

Hereditary angioedema (HAE) is a rare, debilitating and potentially life-threatening disease characterized by recurrent attacks of oedema. With the development of new therapies and better availability of diagnostic tools, important advances have been made. However, the disease still remains frequently misdiagnosed and inadequately treated. Familial Mediterranean fever (FMF) is an autoinflammatory syndrome comprised of serositis, fever, arthritis and skin involvement. Both diseases can cause severe abdominal pain resembling that of acute abdomen. We report a case of three family members that presented with various symptoms that could fit in a clinical picture of both diseases, only to confirm a diagnosis of HAE type II after a diagnostic delay of many years.

Keywords: Familial mediterranean fever; Autoinflammatory disorders; Oedema

INTRODUCTION

Hereditary angioedema (HAE) is a rare debilitating disease characterised by recurrent subcutaneous oedema with variability in frequency, localization and severity that may lead to erroneous diagnosis and diagnostic delay. Abdominal attacks caused by intestinal wall swelling often resemble acute abdomen and lead to unnecessary surgical procedures. Airway oedema can be fatal, therefore a timely diagnosis is important. There are three types of HAE: type I is caused by C1 inhibitor deficiency, type II by abnormal function of C1 inhibitor while its concentration could be normal or elevated.

1. Department of Internal Medicine, Division of Clinical Immunology and Rheumatology, University of Zagreb, School of Medicine, University Hospital Center Zagreb, Zagreb, Croatia

2. Department of Laboratory Diagnostics, University Hospital Center Zagreb, Zagreb, Croatia

Pathogenesis of HAE type III includes estrogen-dependence with factor XII mutation and normal C1 inhibitor concentration and function. The underlying cause of types I and II are mutations in *SERPIN1* gene¹.

Familial Mediterranean fever (FMF) is an autoinflammatory syndrome that occurs primarily in people originating from the Mediterranean basin. Its diagnosis relies mainly on clinical findings of serositis, fever, arthritis or skin involvement². Abdominal pain of varying severity occurs in 95% of patients and may as well resemble a surgical emergency³. During an inflammatory attack, as part of an acute phase response, an elevation of C reactive protein (CRP) and leukocytosis usually occur. A mutation in *MEFV* gene on both alleles occurs in 70%, whereas in 30% of cases only one or no mutation can be detected⁴. NSAIDs are used during attacks and colchicine is the first-line chronic therapy for FMF, where a favorable response to colchicine is considered a minor criteria for diagnosis of FMF².

CASE REPORT

A 48-year-old woman had a history of periodic oedema, predominantly of hands, and abdominal pain that started at the age of 24, during her first pregnancy. She underwent appendectomy, but the microscopic and pathohistological finding of the appendix showed no signs of inflammation. Periodically she had episodes of abdominal pain with ascites and mildly elevated CRP. At the age of 32 she was diagnosed with FMF in a local hospital and started treatment with colchicine, resulting in fewer attacks. No data of C4 testing was available from that time.

Her son also had a history of occasional swelling of hands during childhood, and at the age of 15, he was admitted to a local hospital because of severe abdominal pain, nausea, vomiting and fever. His laboratory tests did not show clear signs of inflammation. Abdominal US and CT scan showed abundant ascites with

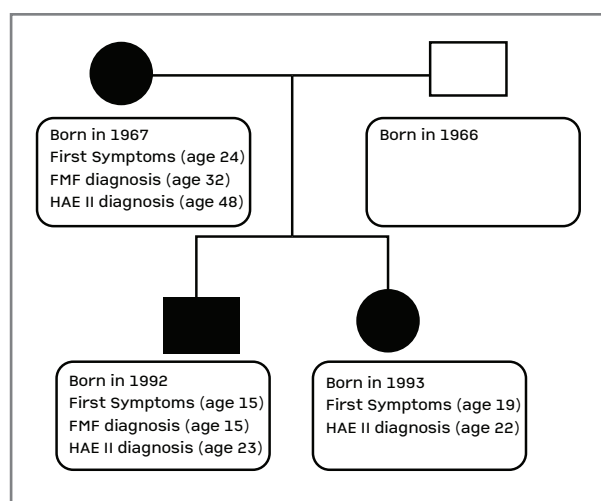


FIGURE 1. Family tree. Black circles represent the mother and daughter, black square represents the son, white square represents the healthy husband.

intestinal wall oedema. Considering the mother's diagnosis, he was also diagnosed with FMF at the local hospital. Colchicine 0.5 mg BID was introduced to therapy, but the patient discontinued it after a few months. Five years after the initial presentation he sought help because of abdominal attacks recurring every two months, so both patients were examined at our outpatient clinic. Initial testing for allergies and autoimmune antibodies (antinuclear antibodies - ANA, extractible nuclear antibodies - ENA, as well as IgE and CH50) were negative. As CH50 was normal, we did not suspect significant alterations in the classical component cascade, so C4 levels weren't tested. Colchicine was again introduced to therapy with satisfying results. Genetic testing for FMF was performed next, and no mutations in sequenced regions of *MEFV* gene were found in either patient. It has been established, though, that they had a heterozygous nucleotide change *R202Q* (*rs 224222*) in exon 2 which could cause a clinical picture associated with FMF. C1 inhibitor concentration was performed and came back normal. Due to technical difficulties, C1 inhibitor function test could not be performed at the time.

At the same time the patient's 19-year-old daughter developed unilateral eyelid and hand oedema that subsided spontaneously the next day. Her immunologic testing and C1 inhibitor concentration didn't show any significant abnormalities. Presumably, she had the same disease as her sibling and mother, possibly a form of an autoinflammatory syndrome - FMF. The father

did not report any symptoms.

During the next 3 years the mother and son had fewer attacks of abdominal pain and oedema of the extremities, sometimes accompanied by arthralgia, while being afebrile, with ongoing colchicine therapy. The daughter was almost asymptomatic and required no treatment.

Routine immunologic test reevaluation after a 3-year period did not show any substantial alterations, but C4 levels weren't performed again because of normal levels of CH50. Finally, C1 inhibitor function test became available and showed a significantly decreased value (mother 10.6%, son 17%, daughter 19.8%; reference value: 70.0-130.0%). Father was also tested and his results came back negative. According to that result and the clinical picture, a diagnosis of HAE type II was established in all three patients. The treatment was also modified accordingly.

Currently, both the mother and the son are treated with on demand therapy (ODT) with conestat alpha at the local hospital for acute attacks and are receiving prophylactic treatment because of increased frequency of attacks and consequentially poor quality of life. At our center, standard of care for HAE prophylactic treatment of female patients is tranexamic acid because of possible adverse effects of androgens (virilization, amenorrhoea). Therefore, the mother is treated with tranexamic acid (1000 mg BID) and the son with danazol (200 mg BID). The daughter did not experience a significant disease burden. She has mild infrequent symptoms usually involving hands and feet that subside spontaneously in a few hours. She did not need ODT with conestat alpha nor any prophylactic treatment. All patients are equipped with icatibant in case of significant laryngeal swelling.

Lately, genetic testing was performed and a mutation of *c.1397G>A* on exon 8 of *SERPING1* gene was confirmed in all three patients, thus confirming the diagnosis of HAE type II.

DISCUSSION

Rare disorders with atypical presentation can sometimes have overlapping symptoms rendering them difficult to diagnose. HAE is an autosomal dominant disease with an almost complete penetrance. It often affects multiple generations in a family. Therapeutic options include acute treatment of an acute attack and prophylactic treatment, whether for short-term pro-

TABLE I. SIMILARITIES IN SYMPTOMS OF FAMILIAL MEDITERRANEAN FEVER AND HEREDITARY ANGIOEDEMA

Familial Mediterranean Fever	Hereditary Angioedema
Age at onset <20 years	Age at onset <20 years
Common duration of attacks 1-3 days	Common duration of attacks 1-3 days
Erysipelas like erythema	Erythema marginatum (prodromal symptom)
(Mono)arthritis (synovitis)	Swelling of periarticular soft tissues
Abdominal pain (peritonitis)	Abdominal pain (oedema of intestinal wall)
Fever	Afebrile*

*Acute infection accompanied by fever may be a triggering factor of an HAE attack.

phylaxis in situations where exposition to certain triggers are expected and long-term prophylaxis where the frequency of attacks seriously affect the patient's quality of life. Treatment of acute attacks consist of ODT therapy with bradykinin receptor antagonist icatibant applied subcutaneously or C1 inhibitor (plasma derived or recombinant) applied intravenously. For short-term prophylaxis, C1 inhibitor replacement and high dose androgens are used. For long-term prophylaxis, also C1 inhibitor replacement is used, as well as androgens or tranexamic acid¹.

HAE symptoms resemble other forms of angioedema and HAE abdominal attacks may mimic a surgical emergency, therefore a delay in diagnosis is not uncommon.

Nationwide surveys in Spain and Denmark indicate a mean delay in diagnosis of 13.1 and 16.3 years^{5,6}. Another survey demonstrates that 313 HAE patients reported visiting an average of 4.4 physicians over an average of 8.3 years before being accurately diagnosed with HAE⁷. A study of 152 HAE type I and II patients from 8 European countries enrolled in Icatibant Outcome Study (IOS) reported a median delay in diagnosis of 8.5 years [0.0–62.0] with an almost significant difference between delay in diagnosis for HAE type I and type II (8.0 [0.0–62.0] versus 21.0 years [0.0–42.0]; $p = 0.051$)⁸. This difference between HAE type I and II diagnostic delay might be due to the fact that the patients are only tested for C1 inhibitor concentration, as was initially the case in our patients as well. Another analysis of IOS study patients reported that 418 of 633 HAE patients had provided misdiagnosis data, while 185 of 418 (44.35%) had one or more prior misdiagnoses, allergic angioedema and appendicitis being the most common⁹. A group of Czech authors analyzed diagnostic delay in one centre of 77 patients diagnosed with HAE type I and II from 1980 and

2013 and found a median diagnostic delay of seven years (range, 0-42)¹⁰. Without an accurate and timely diagnosis patients are at risk of ineffective treatment which may lead to higher morbidity and mortality, as well as unnecessary surgical interventions.

Clinical similarities of HAE and FMF are shown in Table I. A major clinical sign that might help differentiate these diseases is fever which is the most prominent sign in FMF and should be absent in HAE. A confounding factor can be the occurrence of a simultaneous infection causing fever as well as inducing a stress related HAE attack since any infection constitutes as stress and therefore can precipitate an HAE attack. Another differentiating characteristic is pleuritis or pericarditis that are a major criteria in FMF and do not occur in HAE.

The mother in this case was misdiagnosed with FMF and had a fairly mild disease while treated with colchicine which was considered a partial response to therapy, leading to a confirmation of an incorrect diagnosis of FMF.

When her son first presented with symptoms resembling those of FMF (abdominal pain accompanied by fever, unclear history of occasional swelling of hands, sometimes with joint pain) and a positive family history for FMF, a logical assumption of FMF was made since HAE attacks should not be accompanied by fever. However, it is likely that his first HAE abdominal attack was precipitated by an unidentified infection causing fever, therefore misleading to a diagnosis of FMF. The following attacks were not accompanied by fever and he did not have typical arthritis which should have raised suspicion that FMF might not be the correct diagnosis. During further investigation at our hospital, C4 levels were not performed because of a rather clear clinical picture of FMF supposedly resolving after periodic colchicine therapy and normal CH50

screening test. On a routine laboratory check-up, we tested C1 inhibitor concentration and it came back normal. Only after an in-depth analysis of the archived documented medical history obtained from the local hospital where the young patient was hospitalized during his first abdominal attack did we notice decreased levels of C4. All of this resulted in an 8 year diagnostic delay in the son's case and a 24 year delay in the mother's.

Since both FMF and HAE are rare and characterized by fairly similar eluding symptoms they can sometimes cause a diagnostic conundrum (TABLE I). Not many data on FMF mimicking HAE can be found. A case report describes a coexistence of both diseases in a 15-year-old girl with a *R202Q* homozygote mutation in the *MEFV* gene, partial response to colchicine and low levels of C1 inhibitor as well as family history of HAE¹¹. *MEFV* gene mutation has been associated to other complex multifactorial diseases¹² such as Behçet disease¹³, Henoch Schönlein purpura¹⁴, polyarteritis nodosa¹⁵, PFAPA (periodic fever, aphthous stomatitis, pharyngitis, cervical adenitis)¹⁶, ankylosing spondylitis¹⁷, multiple sclerosis¹⁸ and fibromyalgia¹⁹. No association has been reported between HAE and FMF so far.

CONCLUSION

These three patients represent one of two families diagnosed with HAE type II in Croatia. In our case a misdiagnosis of the mother led to a misdiagnosis of her offspring. When dealing with rare and complex diseases such as FMF and HAE, it is important to carefully evaluate and often reevaluate patients, their symptoms and test results. With improved awareness of both diseases among physicians we can decrease the diagnostic delay and initiate adequate treatment earlier.

CORRESPONDENCE TO

Boris Karanovic
Department of Internal Medicine
Division of Clinical Immunology and Rheumatology
University Hospital Centre
Zagreb
E-mail: boris.karanovic@gmail.com

REFERENCES

- Zuraw BL, Christiansen SC. Hereditary angioedema and bradykinin-mediated angioedema. In: Adkinson NF Jr, Bochner BS, Burks W, Busse WW, Holgate ST, Lemanske RF Jr, O'Hehir RE (eds.). *Middleton's Allergy: Principles and practice*, Vol. 1, 8th edn. Philadelphia: Elsevier Saunders; 2014; 588-601.
- Livneh A, Langevitz P, Zemer D, Zaks N, Kees S, Lidar T, et al. Criteria for the diagnosis of familial Mediterranean fever. *Arthritis Rheum*. 1997; 40: 1879-1885.
- Simon A, van der Meer JW, Drenth JP. Familial Mediterranean fever--a not so unusual cause of abdominal pain. *Best Pract Res Clin Gastroenterol*. 2005; 19: 199-213.
- Chen X, Fischel-Ghodsian N, Cercek A, Hamon M, Ogur G, Lotan R et al. Assessment of pyrin gene mutations in Turks with familial Mediterranean fever (FMF). *Hum Mutat*. 1998; 11: 456-460.
- Roche O, Blanch A, Caballero T, Sastre N, Callejo D, Lopez-Trascasa M. Hereditary angio-oedema due to C1 inhibitor deficiency: patient registry and approach to the prevalence in Spain. *Ann Allergy Asthma Immunol*. 2005; 94:498-503.
- Bygum A. Hereditary angioedema in Denmark: a nationwide survey. *Br J Dermatol*. 2009; 161:1153-1158.
- Lunn ML, Santos CB, Craig TJ. Is there a need for clinical guidelines in the United States for the diagnosis of hereditary angioedema and the screening of family members of affected patients? *Ann Allergy Asthma Immunol*. 2010; 104: 211-214.
- Zanichelli A, Magerl M, Longhurst H, Fabien V, Maurer M. Hereditary angioedema with C1 inhibitor deficiency: delay in diagnosis in Europe. *Allergy Asthma Clin Immunol*. 2013; 9: 29.
- Zanichelli A, Longhurst H, Maurer M, Bouillet L, Aberer W, Fabien V, et al. for the IOS Study Group. Misdiagnosis trends in patients with hereditary angioedema from the real-world clinical setting. *Ann Allergy Asthma Immunol* 117 (2016) 394e398.
- Hakl R, Kuklínek P, Kadlecová P, Litzman J. Hereditary angioedema with C1 inhibitor deficiency: Characteristics and diagnostic delay of Czech patients from one centre. *Allergol Immunopathol (Madr)*. 2016; 44: 241-245.
- Bahceci SE, Genel F, Gulez N, Nacaroglu HT. Coexistence of hereditary angioedema in a case of familial Mediterranean fever with partial response to colchicine. *Cent Eur J Immunol*. 2015; 40: 115-116.
- Soriano A, Pras E. Familial Mediterranean fever: Genetic Update. *Isr Med Assoc J*. 2014;16: 274-276.
- Livneh A. Familial Mediterranean fever and Behçet disease. *Clin Exp Rheumatol*. 2003; 21:266.
- Adiv OE, Butbul Y, Nutenko I, Brik R. Atypical Henoch-Schönlein purpura: a forerunner of familial Mediterranean fever. *Isr Med Assoc J*. 2011; 13: 209-211.
- Yalçinkaya F, Özçakar ZB, Kasapçopur O, Öztürk A, Akar N, Bakkalo lu A, et al. Prevalence of the *MEFV* gene mutations in childhood polyarteritis nodosa. *J Pediatr*. 2007; 151: 675-678.
- Berkun Y, Levy R, Hurwitz A, Meir-Harel M, Lidar M, Livneh A, et al. The familial Mediterranean fever gene as a modifier of periodic fever, aphthous stomatitis, pharyngitis, and adenopathy syndrome. *Semin Arthritis Rheum*. 2011; 40: 467-72.
- Akkoc N, Sari I, Akar S, Binicier O, Thomas MG, Weale ME, et al. Increased prevalence of M694V in patients with ankylosing spondylitis: additional evidence for a link with familial mediterranean fever. *Arthritis Rheum*. 2010; 62: 3059-3063.
- Yigit S, Karakus N, Kurt SG, Ates O. Association of missense mutations of Mediterranean fever (*MEFV*) gene with multiple sclerosis in Turkish population. *J Mol Neurosci*. 2013; 50: 275-279.
- Karakus N, Yigit S, Inanir A, Inanir S, Toprak H, Okan S. Association between sequence variations of the Mediterranean fever gene and fibromyalgia syndrome in a cohort of Turkish patients. *Clin Chim Acta*. 2012; 414: 36-40.