

# Chronic skin lichenification as an unusual presentation of eosinophilic granulomatosis with polyangiitis: case report and literature review

Sbrana F<sup>1</sup>, Loggini B<sup>2</sup>, Galimberti S<sup>3</sup>, Coceani M<sup>1</sup>, Latorre M<sup>4</sup>, Seccia V<sup>5</sup>, L'Abbate S<sup>6</sup>, Mosca M<sup>6</sup>, Pasanisi EM<sup>1</sup>, Baldini C<sup>6</sup>

ACTA REUMATOL PORT. 2016;41:158-161

## ABSTRACT

Eosinophilic granulomatosis with polyangiitis (EGPA) is an uncommon ANCA-associated systemic small-vessel necrotizing vasculitis. At times, EGPA presenting manifestations can be very different from the usually recognized disease patterns. We report a 52-year-old female patient with 3 years history of itching. In this period, the patient developed chronic skin lichenification on her legs followed by full-blown ANCA-MPO positive EGPA in combination with blood hypereosinophilia, eosinophilic vasculitis at skin biopsy, subclinical asthma and chronic rhinosinusitis.

**Keywords:** Chronic skin lichenification; Eosinophilic Granulomatosis with Polyangiitis; Hypereosinophilic syndrome.

## INTRODUCTION

Eosinophilic granulomatosis with polyangiitis (ex Churg-Strauss syndrome - EGPA) is a rare, potentially life-threatening, ANCA-associated systemic small-vessel necrotizing vasculitis, characterized by peripheral blood hyper-eosinophilia and tissue infiltration by eosinophils, occurring in individuals with asthma and often sinonasal polyposis<sup>1</sup>. Classically, EGPA is diagnosed after excluding other conditions such as hypereosinophilic syndrome, reactive conditions (allergic reactions, parasitic infections, adrenal insufficiency), eosinophilia associated to solid advanced neoplasias or hematological disorders (lymphomas, chronic myeloproliferative disorders, chronic myelomonocytic leukemia), autoimmune skin diseases and pulmonary eosinophilias<sup>2</sup>.

At times, EGPA presenting manifestations can be very different from the usually recognized disease patterns and this complexity may delay early diagnosis and treatment. Such uncommon presentations require a systemic multidimensional approach to allow a proper diagnosis and the administration of early and successful conservative therapy.

In the present report, we describe the case of a patient presenting with skin chronic lichenification and peripheral blood hypereosinophilia. The diagnosis of EGPA in this patient was particularly challenging because of the predominantly dermatological features overwhelming asthma and the other classical EGPA clinical manifestations. This case highlights the importance of a multidisciplinary approach for the diagnosis of the disease and the central role of cutaneous histology in confirming the diagnosis of vasculitis and in avoiding a delayed or improper management.

**CASE REPORT**

In 2011, a 52-year-old woman was referred to our outpatient clinic due to a long-standing history (3 years) of itching for which she had previously been diagnosed with "nodular prurigo". The patient had already undergone blood tests, which revealed a transient increase in IgE (1066 UI/ml) and a transient positive FANHEP-2 test (1:160). A skin biopsy had also been performed, but was not specific showing a framework

1. Fondazione Toscana Gabriele Monasterio

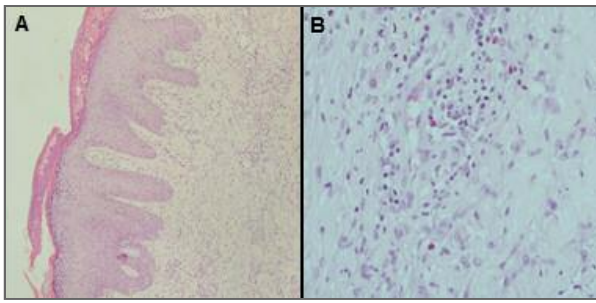
2. Pathological Anatomy Institute, University of Pisa

3. Department of Oncology, Transplants and New Medical Techniques, Hematology Unit, University of Pisa

4. Cardio Thoracic and Vascular Department, University of Pisa

5. 1st Ear Nose Throat Unit, Azienda Ospedaliero Universitaria Pisana

6. Department of Internal Medicine, U.O. Rheumatology, University of Pisa



**FIGURE 1.** Lesional skin biopsy on the upper leg with exoserosis, parakeratosis, epidermal hyperplasia and dermal infiltrate (Panel A) and dermal perivascular infiltrate with eosinophils (Panel B).

compatible with lesions due to scratching associated with numerous eosinophils (Figure 1). Topic steroid therapy had been undertaken in association with cyclosporine and, subsequently, azathioprine, both withdrawn due to an increase in hepatic cytolysis indices.

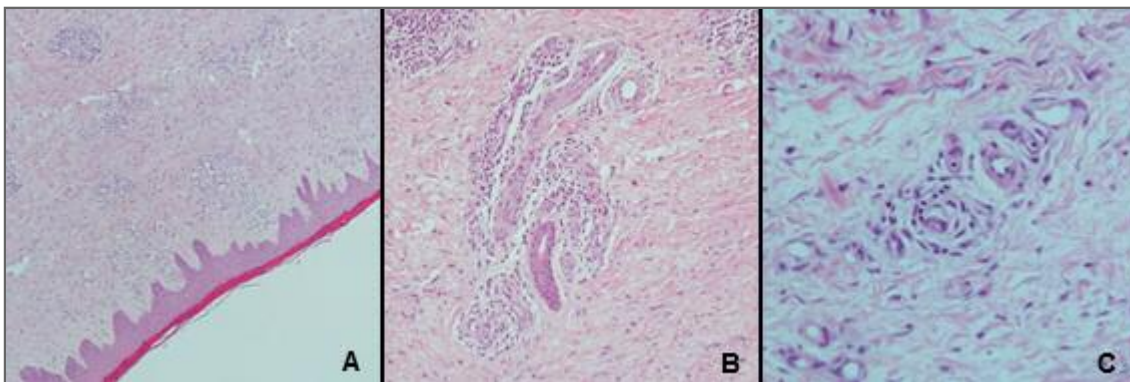
Comorbidities included obesity (height 160 cm, weight 92 kg, body mass index 35.9 Kg/m<sup>2</sup>), chronic rhinosinusitis, and dyslipidemia, the latter of which under statin treatment (simvastatin 10 mg/day).

At outpatient clinic admission, the patient presented scratching lesions on her chest and on the four limbs, improntable leg edema and referred effort dyspnea. She was assuming prednisone 5 mg/day. Blood tests were repeated and confirmed the increase of the IgE levels (2787 UI/ml). We also documented abnormalities in the eosinophil count (1470/μL – 4.8%). Anti-neutrophil cytoplasmic antibodies, antinuclear antibodies, FIP1L1-PDGFRα fusion gene, tryptase,

celiac disease screening and fecal parasites research were negative. Pulmonary function tests, performed during steroid therapy, revealed signs of restrictive disease in the absence of inducibility of bronchial reactivity to methacholine. Echocardiogram, total body CT scan and abdominal ultrasound were normal. Allergy skin tests for common allergens were negative. Electromyography and nerve conduction study were normal. A muscular biopsy and a bone marrow biopsy were performed to complete the differential diagnosis algorithm for hypereosinophilic syndromes, but were normal (1.2/HPF mean value of tryptase positive cells at the bone marrow biopsy).

Subsequently, the corticosteroid therapy was increased (prednisone 20 mg/day) obtaining a gradual improvement of the skin lesions and a decrease in the IgE levels (262 UI/ml).

Over the follow-up, the patient showed a significant clinical stability while maintaining the chronic steroid therapy. After one year she presented a relapse of her cutaneous manifestations with lesions due to scratching on the chest and abdomen and chronic skin lichenification on her legs. Clinical and biohumoral reassessment revealed higher IgE levels (377 UI/ml), an increase in the peripheral blood eosinophil count (2200/μL – 18%) and a positive ANCA-MPO test at the ELISA test. ANCA MPO positivity was confirmed in a second evaluation. Pulmonary evaluation was repeated as well, with evidence of an increase in exhaled nitric oxide (eNO 44 ppb) and a mild change in induced sputum cell (10%). Those findings in course of steroid therapy were compatible, even in the absence of respiratory symptoms, with mild bronchial asthma.



**FIGURE 2.** Lesional skin biopsy on the upper leg with slight hyperplastic epidermis with an inflammatory perivascular infiltrate in dermis (Panel A); dermal perivascular lymphocytic infiltrate with occasional histiocytes (Panel B) and sparse eosinophils in the infiltrate (Panel C).

A second skin biopsy was repeated and showed dermis with mild fibrosis and lympho-histiocytic infiltrates, focal aspects compatible with vasculitis, sparse cells CD117 and tryptase positive (20/HPF) located predominantly in perivascular seat and eosinophils (Figure 2). A bone marrow biopsy was repeated and allowed us to definitively rule out the diagnosis of mastocytosis. On the basis of the patient's history, laboratory tests and skin biopsy results, which were compatible with cutaneous eosinophilic vasculitis, a diagnosis of EGPA was made. Specific therapy with methotrexate was undertaken obtaining a complete remission of the patient's skin lesions. After an 18 month follow-up the patient is on maintenance therapy with weekly doses of methotrexate (10 mg/week). She is still asymptomatic and her blood tests are completely normal. ANCA-MPO remain positive, but at a borderline level.

## DISCUSSION

We describe the case of a patient who during follow-up gradually developed a full-blown ANCA-MPO positive EGPA (ACR criteria, 1990<sup>3</sup>). Indeed, she presented a combination of i) blood hypereosinophilia; ii) eosinophilic vasculitis at skin biopsy; iii) mild asthma; iv) chronic rhinosinusitis. In our case, the diagnosis was particularly challenging due to the fact that the pre-

senting and predominant disease feature was represented by a skin vasculitis evolving over the years in chronic lichenification. By contrast, ears, nose & throat (ENT) and lung involvement in our patient were mild and/or subclinical, probably mitigated by the chronic use of low-medium steroid doses, undertaken for the control of the skin lesions. Late-onset refractory asthma is generally considered the hallmark feature of EGPA. Therefore, the absence of a clear history of bronchospastic symptoms or paroxysmal dyspnea was probably one of the main reasons for the delayed diagnosis in our patient.

To date, very few cases of EGPA without overt bronchial asthma have been reported. An accurate review of the literature through PubMed search (1 January 1986–30 June 2014; terms: “Churg–Strauss syndrome” or “Eosinophilic granulomatosis with polyangiitis” and “atypical presentation”, “uncommon presentation” “non-asthmatic”, “without asthma”) retrieved 15 case reports<sup>4-18</sup>. Table I summarizes the available literature data. The vast majority of the patients with atypical EGPA presentation were male, with a male: female ratio of 12:3 (median age: 40 years, range 2-68 years). Noteworthy, renal involvement was relatively common in this subset of patients, being detected in 5 out of 15 cases. The first take-home message outlined by this case report is, therefore, that, since non-asthmatic cases of EGPA have been reported, absence of overt asthmatic

**TABLE I. NON-ASMATIC EGPA: LITERATURE REVIEW (PUBMED SEARCH FROM 1 JANUARY 1986 TO 30 JUNE 2014)**

Author, year	Country	Sex (M/F)	Age	ANCA status	Organ involvement
Jessurun J., 1986	USA	M	14 yr	N/A	skin, thymus
Sasaki A., 1988	Japan	M	54 yr	N/A	heart, lung
Chen KR., 1992	Japan	M	38 yr	N/A	skin, heart, pns
Yamashita Y., 1998	Japan	M	61 yr	p-ANCA	pns, kidney
Yamamoto T., 1998	Japan	F	68 yr	p-ANCA	kidney
Malik TQ., 2002	Saudi Arabia	M	32 yr	p-ANCA	pns
Moor JW., 2002	UK	M	53 yr	N/A	ENT, supraclavicular mass
Sevinc A., 2003	Turkey	M	21 yr	N/A	lung
Morimatsu Y., 2003	Japan	F	68 yr	N/A	heart, lung, pns
Sharma BK., 2004	India	F	35 yr	p-ANCA	skin, lung, pns
Kawakami T., 2005	Japan	M	42 yr	ANCA neg	skin
Hamdan MA., 2007	United Arab Emirates	M	2 yr	N/A	gastrointestinal
Chemmalakuzhi AJ., 2008	USA	M	36 yr	ANCA neg	kidney
Prochnicka A., 2009	Poland	M	48 yr	p-ANCA	kidney
Kaul A., 2014	India	M	58 yr	p-ANCA	pns, kidney, gastrointestinal

symptoms should not be considered as an absolute criterion to exclude the diagnosis of EGPA.

On the other hand, despite not included in the classification criteria, cutaneous manifestations should not be overlooked as presenting features of the disease. Skin involvement has been frequently reported in EGPA occurring in 40–81% of EGPA patients, and it has been described in about 14% of patients at the disease presentation. Palpable purpura and urticarial lesions were the most common cutaneous manifestations reported in different cohorts. Less common manifestations included papular/nodular lesions, livedo reticularis, cutaneous infarcts, ulcerations gangrene and bullous lesions. Cutaneous histology might reveal skin vasculitis, eosinophil infiltration, and extravascular granuloma eventually leading to the correct diagnosis. Considering that the new 2012 Revised International Chapel Hill Consensus Conference Nomenclature of Vasculitides outlined the vasculitic nature of EGPA<sup>19</sup>, it is likely that skin manifestations in the near future will receive greater emphasis in the diagnostic algorithm of the disease. In our case, skin biopsy results were crucial for the diagnosis of EGPA, allowing us to rule out systemic mastocytosis, atopic dermatitis and nodular prurigo. Bone marrow biopsies and muscular biopsy further reinforced EGPA diagnosis excluding idiopathic hypereosinophilic syndrome, hematological neoplasia and systemic mastocytosis.

Unfortunately, specific and reliable biomarkers able to distinguish EGPA from mimicking disorders are still lacking. Therefore, in clinical practice a non-negligible percentage of patients might remain undiagnosed. In complex cases, like the one presented in this report, a multidisciplinary health care approach is mandatory to identify and properly manage even those patients with EGPA and atypical presenting features.

#### CORRESPONDENCE TO

Francesco Sbrana  
Via Giuseppe Moruzzi, 1, 56124 Pisa PI, Itália  
E-mail: francesco.sbrana@ftgm.it

#### REFERENCES

1. Churg J, Strauss L. Allergic granulomatosis, allergic angiitis, and periarteritis nodosa. *Am J Pathol.* 1951; 27: 277-301.
2. Mouthon L, Dunogue B, Guillevin L. Diagnosis and classification of eosinophilic granulomatosis with polyangiitis (formerly named Churg-Strauss syndrome). *J Autoimmun.* 2014; 48-49: 99-103.
3. Masi AT, Hunder GG, Lie JT, et al. The American College of Rheumatology 1990 criteria for the classification of Churg-Strauss syndrome (allergic granulomatosis and angiitis). *Arthritis Rheum* 1990; 33: 1094-1100.
4. Jessurun J, Azevedo M, Saldana M. Allergic angiitis and granulomatosis (Churg-Strauss syndrome): report of a case with massive thymic involvement in a nonasthmatic patient. *Hum Pathol.* 1986; 17: 637-639.
5. Sasaki A, Hasegawa M, Nakazato Y, Ishida Y, Saitoh S. Allergic granulomatosis and angiitis (Churg-Strauss syndrome). Report of an autopsy case in a nonasthmatic patient. *Acta Pathol Jpn.* 1988; 38: 761-768.
6. Chen KR, Ohata Y, Sakurai M, Nakayama H. Churg-Strauss syndrome: report of a case without preexisting asthma. *J Dermatol.* 1992; 19: 40-47.
7. Yamashita Y, Yorioka N, Taniguchi Y, et al. Nonasthmatic case of Churg-Strauss syndrome with rapidly progressive glomerulonephritis. *Intern Med.* 1998; 37: 561-563.
8. Yamamoto T, Yoshihara S, Suzuki H, Nagase M, Oka M, Hishida A. MPO-ANCA-positive crescentic necrotizing glomerulonephritis and tubulointerstitial nephritis with renal eosinophilic infiltration and peripheral blood eosinophilia. *Am J Kidney Dis.* 1998; 31: 1032-1037.
9. Malik TQ, Youmbissi TJ, Gacha R, Abdelrahman M, Al-Khursany AI, Karkar A. Atypical presentation of Churg-Strauss syndrome: another "forme fruste" of the disease? *Am J Med Sci.* 2002; 324: 276-278.
10. Moor JW, U-King Im J, MacDonald AW, Whitehead E. Limited form of Churg-Strauss syndrome presenting as a mass in the neck. *J Laryngol Otol.* 2002; 116: 966-968.
11. Sevinc A, Hasanoglu HC, Gokirmak M, Yildirim Z, Baysal T, Mizrak B. Allergic granulomatosis and angiitis in the absence of asthma and blood eosinophilia: a rare presentation of limited Churg-Strauss syndrome. *Rheumatol Int.* 2004; 24: 301-304.
12. Morimatsu Y, Kinoshita M, Koga T, Aizawa H. A case of allergic granulomatosis and angiitis without symptoms of asthma. *Nihon Kokyuki Gakkai Zasshi.* 2003; 41: 655-659.
13. Sharma BK, Daga MK, Sharma M. A limited form of Churg-Strauss syndrome presenting without asthma and eosinophilia. *Med J Aust.* 2004; 181: 498-499.
14. Kawakami T, Soma Y, Kawasaki K, Kawase A, Mizoguchi M. Initial cutaneous manifestations consistent with mononeuropathy multiplex in Churg-Strauss syndrome. *Arch Dermatol.* 2005; 141: 873-878.
15. Hamdan MA, Al-Rumaithi S, Tolaymat N, Ionescu G, Al-Ashari M, El-Teraifi H. Churg-Strauss syndrome presenting as an abdominal mass in a non-asthmatic child. *Ann Trop Paediatr.* 2007; 27: 311-314.
16. Chemmalakuzhy AJ, Zhou XJ, Hedayati SS. ANCA-negative glomerulonephritis associated with nonasthmatic Churg-Strauss syndrome. *Nat Clin Pract Nephrol.* 2008; 4: 568-574.
17. Próchnicka A, Zelichowski G, Wojtecka A, et al. Atypical clinical presentation of Churg-Strauss syndrome with rapidly progressive glomerulonephritis: case report. *Pol Arch Med Wewn.* 2009; 119: 830-833.
18. Kaul A, Sharma RK, Jaisuresh KS, Agrawal V. Crescentic glomerulonephritis in non-asthmatic Churg-Strauss syndrome. *Saudi J Kidney Dis Transpl.* 2014; 25: 402-407.
19. Jennette JC, Falk RJ, Bacon PA, et al. 2012 revised International Chapel Hill Consensus Conference Nomenclature of Vasculitides. *Arthritis Rheum.* 2013; 65: 1-11.