

# Good response to rituximab in a patient with granulomatosis with polyangiitis and pulmonary, renal manifestations and ophthalmoplegia

Díez-Morrondo C<sup>1</sup>, Pantoja L<sup>1</sup>, Fernández R<sup>2</sup>, Brañanova P<sup>3</sup>, López A<sup>4</sup>, Alexis D<sup>5</sup>

ACTA REUMATOL PORT. 2016;41:74-77

## ABSTRACT

Cyclophosphamide (CYC) is a classical drug for the treatment of severe granulomatosis with polyangiitis (GPA). However, a considerable number of patients are resistant to standard treatment and it can cause substantial toxicity. Therefore, alternative agents should be considered in refractory cases. We report the successful use with rituximab (RTX) in a 70-year-old patient diagnosed with GPA who developed ophthalmoplegia, an uncommon complication of GPA. The patient also had upper and lower respiratory tract involvement and kidney manifestations which also improved. We review the causes of ophthalmoparesis and the treatment with RTX in GPA.

**Keywords:** Rituximab; granulomatosis with polyangiitis; ophthalmoplegia

## INTRODUCTION

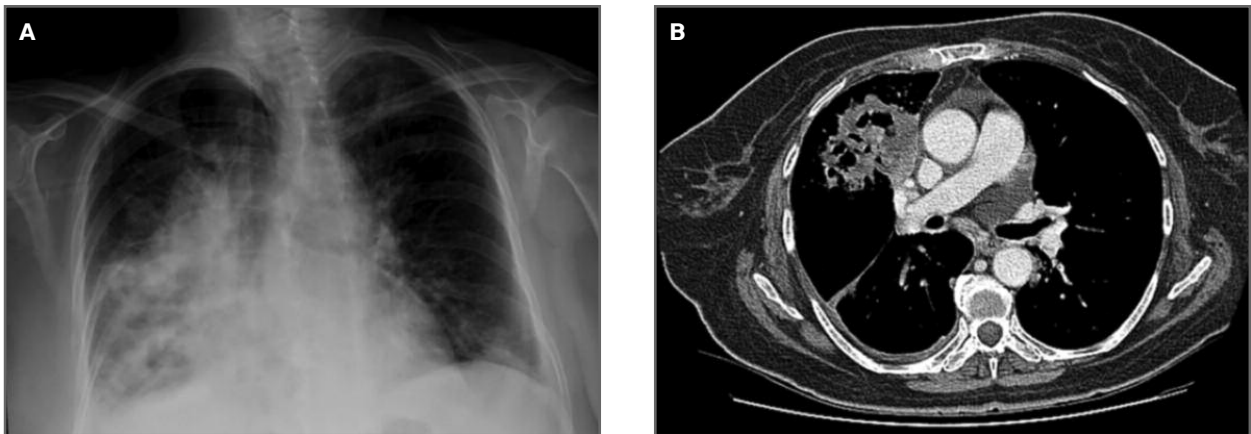
Granulomatosis with polyangiitis (GPA), previously called Wegener's granulomatosis, is a multisystem disorder that typically involves the upper respiratory tract, lungs and kidneys<sup>1</sup>. Ophthalmoplegia is an uncommon manifestation of GPA, especially in the absence of a pseudotumor of the orbit. Although the conventional induction regimen for GPA consists of cyclophosphamide (CYC) and corticoids, rituximab (RTX) has been used in patients with refractory disease. We report the case of a patient with refractory GPA who responded to RTX.

## CASE REPORT

A 70-year-old woman patient was first admitted to the department of Pneumology, in April 2011, with initial manifestations of fever, malaise, rhinorrhea and cough with mild hemoptysis. The patient had a history of sensorineural deafness and one month before she had been examined by a dermatologist because of a skin papule on her left leg. A biopsy was performed, evidencing a granulomatous dermatitis.

Laboratory tests were significant for normocytic normochromic anemia (hemoglobin 10.2 g/dl), mild leukocytosis (12.000/ml), thrombocytosis (522.000/ml), erythrocyte sedimentation rate (ESR) 88 mm/h and C-reactive protein (CRP) 3.6 mg/dl (normal range 0-0.8). Besides, chest X-ray (Figure 1.A) and computed tomography scan (TC) (Figure 1.B) showed multiple bilateral excavated nodules. Since the patient had already the diagnosis of granulomatous dermatitis we thought in sarcoidosis, tuberculosis and GPA as possible differential diagnosis. A transbronchial biopsy revealed giant cells and granulomatous chronic inflammation. Microbial analysis of the bronchoalveolar lavage and blood analysis allowed us to exclude fungal, bacterial or tuberculous infections. TC of the sinuses demonstrated bilateral maxillary, ethmoid and sphenoid air cell opacification. Nasopharyngoscopy showed erosive nasal crusting and an audiometry confirmed a moderate sensorineural hearing loss. Blood test revealed strong positivity for PR3-ANCA (753 U) and a diagnosis of GPA was made. There was no evidence of kidney involvement. The Birmingham Vasculitis Activity Score for Wegener Vasculitis (BVAS/WG) was of 11. She was started on high doses of corticosteroids (1 mg/kg) and pulse intravenous cyclophosphamide (CYC) (10 mg/kg) with trimethoprim/sulfamethoxazole prophylaxis, a treatment that rapidly improved her

1. Department of Rheumatology/Hospital del Bierzo  
 2. Department of Neumology/Hospital del Bierzo  
 3. Department of Radiology/Hospital del Bierzo  
 4. Department of Ophthalmology/Hospital del Bierzo  
 5. Department of Internal Medicine/Hospital del Bierzo



**FIGURE 1.** A) Chest imaging at hospital admission showing extensive alveolar infiltrates involving the lower and medium right lobe and the lower left lobe. B) Thoracic chest scan demonstrated multiple excavated nodules, some of them with necrotic appearance, involving the upper and lower right lobe and the left lower lobe

general condition and led to the resolution of hemoptysis. She was discharged on tapering orally corticoids and intravenously administered CYC every 3 weeks during 6 months (April-October 2011). During that period, despite immunosuppressive treatment we could not control neither the inflammatory syndrome (ESR 42 mm/h and CRP 1.2 mg/dl) nor the upper respiratory tract manifestations. She experienced recurrence of headaches, nasal obstruction and epistaxis. However, she had a good response in the lung and the infiltrates disappeared.

In November 2011, the patient presented for an urgent visit with headache, fever, vomiting, cough and blurred vision in the right eye. A normal lumbar puncture ruled out meningitis. Examination revealed generalized restriction of her right eye movements and a paralysis of the supraduction of the left eye. There were no signs of papilledema.

CRP and ESR were elevated and the PR3-ANCA titer was of 53 U. Chest radiograph disclosed moderate infiltrates again. An orbital TC and a magnetic resonance imaging of sinus and cerebral were performed but no evidence of an orbital granuloma or any mass was found (Figure 2 A,B). Both imaging test showed pansinusopatia but they did not reveal bone erosion of the wall of sinus, extramuscle involvement or infiltration, compression or neuritis of the optic nerve. Nor signs of meningeal involvement were found.

Treatment modalities included 3 days of high-dose intravenous methylprednisolone (1000 mg) and RTX (four weekly doses of 375 mg/m<sup>2</sup>). The patient showed a good and quickly response. After a month, she had

recovered the visual acuity and only a mild paresis of abduction of right eye rested. The lung infiltrates also disappeared.

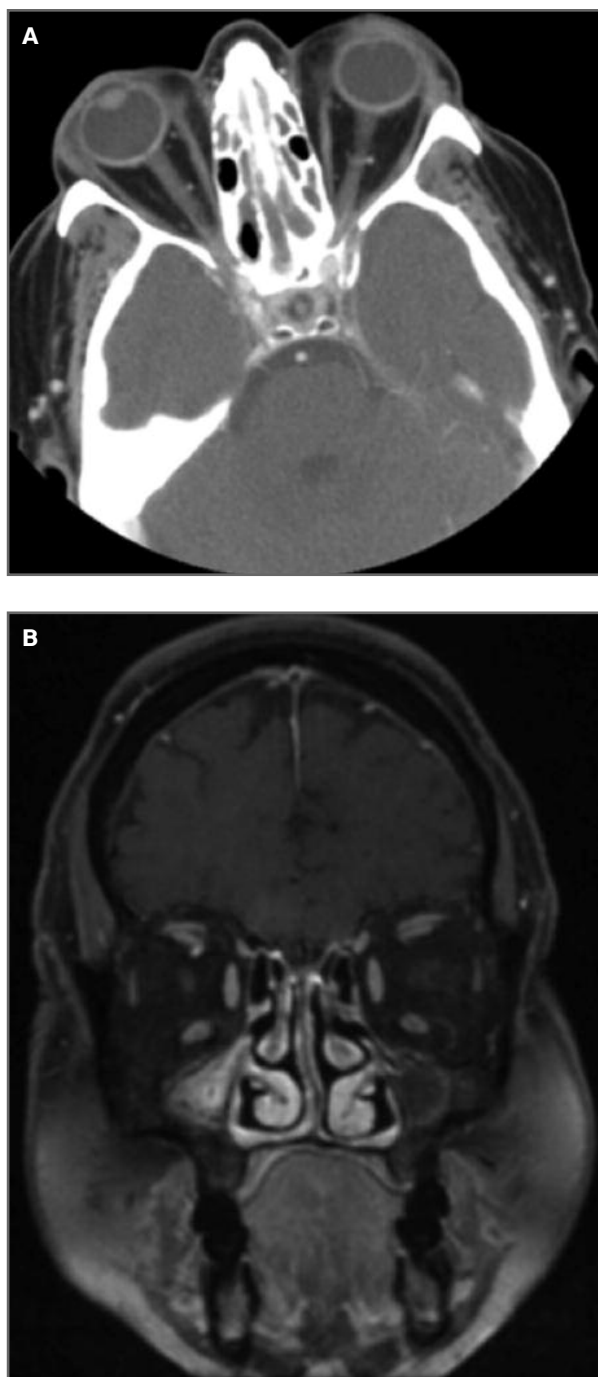
During 18 months of follow-up, the patient was asymptomatic, BVAS/WG decreased to 1, c-ANCA, CRP and ESR were negative, and prednisone had been reduced to 2.5 mg/daily. As a maintenance therapy, we used azathioprine (100 mg/day), which was switched to subcutaneous methotrexate (20 mg/week) a few months later due to liver abnormalities with azathioprine.

In July 2013, she had a third relapse, complaining of malaise and headaches. Laboratory investigations showed increased acute phase reactants, negative ANCA, impaired renal function (serum creatinine 3 mg/dl) and microscopic hematuria. Urinalysis and cytology were negative.

A new course of RTX was administered and prednisone was increased to 30 mg daily. As a maintenance therapy, we switched to mycophenolatemofetil because of the renal involvement. She quickly recovered the renal function and one month later, she had a normal serum creatinine, the hematuria also disappeared. No further courses of RTX have been required on follow-up.

## DISCUSSION

Granulomatosis with polyangiitis, previously called Wegener's granulomatosis, is a small vessel vasculitis characterized by necrotizing granulomatous inflam-



**FIGURE 2.** A, B) Orbital TC and magnetic resonance showed pansinusopatia but they did not reveal granuloma or orbital mass. No bone erosion of the wall of sinus, extramuscle infiltration, compression or neuritis of the optic nerve were found

mation, vasculitis of the upper and lower respiratory tracts and focal necrotizing glomerulonephritis<sup>1</sup>. External ophthalmoparesis is common in patients with pseudotumor of the orbit due to nerve impingement or physical block of the movement of the extraocular muscles by the mass<sup>2</sup>. Pachymeningitis can be complicated by cranial neuropathies in 50% of cases, usually with multiple nerve involvement, including oculomotor ones<sup>3,4</sup>. Apart from these cases, external ophthalmoplegia can be due to a local granulomatous or vasculitic process affecting the oculomotor nerves<sup>1</sup>. In our patient, imaging study did not reveal a mass or orbital granuloma or meninges thickening. We admitted the diagnosis of oculomotor neuropathy due to a local vasculitic process, as possible explanation for this patient's ophthalmoparesis.

CYC induction regimens for antineutrophil cytoplasmic antibody (ANCA) – associated vasculitis are effective in 70-90% of patients, but they are associated with high rates of adverse events<sup>5</sup>. Observational studies investigating the efficacy of RTX in refractory GPA have been published in the past years, most of which reported high rates of remission (80%)<sup>5</sup>. However, clearly dissociated responses were observed, with constitutional and vasculitis-related symptoms often achieving complete responses within days or weeks, and granulomatous-related manifestations regressing more slowly or not at all, particularly for orbital pseudotumors<sup>6</sup>. It may be speculated that a different inflammatory environment of orbital lesions leading to sustained granuloma formation and induction of fibrous tissue may account for the relative resistance towards immunosuppressant agents including RTX<sup>7</sup>. In our patient, the ophthalmoparesis is thought to be due to a vasculitic process affecting the oculomotor nerves instead of an orbital granuloma, which may be the reason for the quick response observed to RTX.

Two studies comparing RTX and CYC in treating ANCA-related vasculitides were published in July 2010<sup>8,9</sup>. In the RAVE study with 197 patients, RTX was not inferior to daily doses of CYC in remission induction and even showed higher efficacy in relapsing cases<sup>8</sup>. Again, RTX and CYC were compared in 44 cases of ANCA-related renal vasculitis in the Rituximab in Vasculitis (RITUXVAS) study, and no superiority was observed compared with CYC in remission induction, although sustained-remission rates were high in both groups (76% in RTX group, 82% with CYC)<sup>9</sup>. Recently, two studies were undertaken to describe GPA clinical responses to RTX used for remission and mainte-

nance therapy<sup>10,11</sup>. In both studies, RTX was able to induce GPA remission and seemed to maintain remission better than other agents, but it was discontinued in one-third of the patients because of adverse events (hypogammaglobulinaemia and infections)<sup>10,11</sup>.

In conclusion, RTX seems an effective treatment for refractory cases of GPA. In our patient RTX was useful to treat the most common manifestations of GPA such as upper and lower respiratory tract involvement and kidney manifestations but it was also effective in treating an uncommon complication like ophthalmoplegia.

#### CORRESPONDENCE TO

Diez-Morrondo C  
Hospital del Bierzo.  
C/Médicos sin Fronteras, 7.  
24404 Ponferrada (León)  
Spain  
E-mail: cdiezmorrondo@saludcastillayleon.es

#### REFERENCES

- Söderström A, Revaz S, Dudler J. (2013) Cranial neuropathies in granulomatosis with polyangiitis (Wegener's): a case-based review. *Clin Rheumatol* Published Online First: 19 December 2013. doi: 10.1007/s10067-013-2420-2422.
- Nishino H, Rubino FA, DeRemee RA, Swanson JW, Parisi JE. Neurological involvement in Wegener's granulomatosis: an analysis of 324 consecutive patients at the Mayo Clinic. *Ann Neurol* 1993; 33: 4-9.
- López R, García J, Campos J, Mallo N, Alende MR. Manifestaciones neurológicas de la granulomatosis de Wegener. *Caso Clínico. Rev Méd Chile* 1997; 135: 913-916.
- Sharma A, Kumar S, Wanchu A, Lal V, Singh R, Gupta V, et al. Successful treatment of hypertrophic pachymeningitis in refractory Wegener's granulomatosis with rituximab. *Clin Rheumatol* 2010; 29: 107-110.
- Cartin-Ceba R, Golbin JM, Keogh KA, Peikert T, Sánchez-Meñéndez M, Ytterberg SR, Fervenza FC, Specks U. Rituximab for remission induction and maintenance in refractory granulomatosis with polyangiitis (Wegener's): ten-year experience at a single center. *Arthritis Rheum* 2012; 64: 3770-3778.
- Aouba A, Pagnoux C, Bienvenu B, Mahr A, Guillevin L. Analysis of Wegener's granulomatosis responses to rituximab: current evidence and therapeutic prospects. *Clin Rev Allergy Immunol* 2008; 34: 65-73.
- Holle JU, Dubrau C, Herlyn K, Heller M, Ambrosch P, Noelle B, Reinhold-Keller E, Gross WL. Rituximab for refractory granulomatosis with polyangiitis (Wegener's granulomatosis): comparison of efficacy in granulomatous versus vasculitic manifestations. *Ann Rheum Dis* 2012; 71: 327-333.
- Stone JH, Merkel PA, Spiera R, Seo P, Langford CA, Hoffman GS et al. Rituximab versus cyclophosphamide for ANCA-associated vasculitis. *N Engl J Med* 2010; 363: 221-232.
- Jones B, Cohen J, Hauser T, Luqmani R, Morgan M et al. Rituximab versus Cyclophosphamide in ANCA-Associated Renal Vasculitis. *N Engl J Med* 2010; 363: 211-220.
- Roubaud-Baudron C, Pagnoux C, Méaux-Ruault N, Grasland A, Zoulim A, LE Guen J et al. Rituximab maintenance therapy for granulomatosis with polyangiitis and microscopic polyangiitis. *J Rheumatol* 2012; 39: 125-130.
- Besada E, Koldingsnes W, Nossent JC. Long-term efficacy and safety of pre-emptive maintenance therapy with rituximab in granulomatosis with polyangiitis: results from a single centre. *Rheumatology (Oxford)* 2013; 52: 2041-2047.