

Surgical management of cervical spine instability in rheumatoid arthritis patients

Marques PM¹, Cacho-Rodrigues P², Ribeiro-Silva M³, Linhares D⁴, Negrão P², Pinto R², Neves N³

ACTA REUMATOL PORT. 2015;40:34-39

ABSTRACT

Aim: Cross-sectional study that aims to evaluate the results of cervical spine surgeries due to rheumatoid arthritis (RA) instability, between January of 2000 and of 2012 in a main Portuguese centre.

Methods: Patients followed on Rheumatology department submitted to cervical spine fusion due to atlanto-axial (AAI), sub-axial (SAI) or cranio-cervical (CCI) instabilities between 2000-2012 were included. Information about the surgical procedure and associated complications was gathered. Imagiologic and clinical indexes before and after surgery (as anterior and posterior atlanto-axial interval and Ranawat index) were evaluated and compared using adequate statistics.

Results: Forty-five patients with RA were included: 25 with AAI, 13 with CCI and 7 with SAI. Ten AAI and 4 CCI patients were submitted to wiring stabilization techniques; 15 AAI and 9 CCI patients to rigid ones; and in all patients with SAI an anterior cervical arthrodesis was chosen. There is a significant increase in PADI and a decrease in AADI in the postoperative evaluation ($p < 0,05$) that only remains significant when rigid systems were used. After surgery the Ranawat index decreased ($p < 0,05$) and no patient showed a deterioration of neurological condition. The complication rate was of 23,1%, with 5 mal-unions.

Conclusion: Surgical management of cervical column instabilities in patients with rheumatoid arthritis is a relatively safe procedure, with a high rate of neurologic improvement. Rigid techniques seem to lead to a

better imagiological improvement when compared to wiring ones.

Keywords: Cervical spine; Surgery; Rheumatoid arthritis.

BACKGROUND

Rheumatoid arthritis (RA) is the most prevalent chronic inflammatory joint disease, with an estimated prevalence of 1%. It has an unknown aetiology and affects several joints. When concerning axial regions, cervical column (CC) is the most affected segment, following only feet and hands in general joint RA involvement¹⁻³. Furthermore, RA is the most common CC inflammatory pathology⁴.

Although RA is more common in females, the literature shows that advanced CC disease is more common in men⁵. RA causes ligament degenerescence, mainly in upper CC, leading to an increased laxity, instability and subluxation of vertebral bodies⁶⁻⁸. CC affection, can present in 3 different ways, sometimes conjoined. The atlanto-axial instability (AAI), between C1 and C2, is the most common one, appearing in around 65% of patients. Sometimes it is associated with cranio-cervical instability (CCI), which appears in 20% of patients⁹. The less frequent one, sub-axial instability (SAI) can be seen in almost 15% of patients.

CC involvement in patients with RA can lead to life-threatening situations, with neurologic deficits and comorbidities that make the early diagnosis a clue step in what concerns to RA patients' management. The surgical approach has as primary goal the stability of the CC, in order to avoid progression of neurologic damage. Although not being clearly defined when a patient should be referred to surgery, recent publications showed that early referral is more effective in preventing additional damage^{10,11}.

1. Serviço de Ortopedia e Traumatologia, Unidade Local de Saúde do Alto Minho, Viana do Castelo – Portugal
 2. Serviço de Ortopedia, Centro Hospitalar São João; Serviço de Ortopedia, Faculdade de Medicina, Universidade do Porto
 3. Serviço de Ortopedia, Centro Hospitalar São João; Serviço de Ortopedia, Faculdade de Medicina, Universidade do Porto; INEB – Instituto de Engenharia Biomédica, Porto – Portugal
 4. CIDES, Faculdade de Medicina, Universidade do Porto – Portugal

This cross-sectional study aims to evaluate the results of CC surgeries due to RA instability, between January of 2000 and of 2012 in a main Portuguese centre.

METHODS

A retrospective analysis of clinical files of all patients with RA followed on Rheumatology Unit was performed, and those submitted to a CC fusion due to AAI, SAI or CCI, between January of 2000 and 2012 where included. When data was not available on the clinical records, patients were contacted. Patients whose records had relevant missing clinical or imagiological data were excluded.

Records were searched for: demographic characteristics, type of instability and surgery performed, clinical state before the surgery and in the most recent appointment, Ranawat neurologic index¹² and surgical complications, as vascular or neurologic lesions, infection, re-operation and non-union. X-rays and CT where evaluated for: anterior atlanto-axial interval (AADI), posterior atlanto-axial interval (PADI), Ranawat line, all before surgery and in the last follow-up visit. Rates and between-evaluations changes of individual parameters were calculated, when applicable. Ranawat neurologic classification is used to describe the severity of neurologic impairments as a result of an inflammatory disease. It consists of 3 classes: class I: patients have no neurologic deficits; class II: patients have subjective weakness with hyperreflexia and/or dysesthesia; and class III: patients have objective findings of weakness and longtract signs (IIIA: able to walk,

IIIB: quadriparetic and unable to walk, bedridden, or requires the use of a wheelchair)¹².

Bone fusion was defined as the presence of bony bridge between adjacent vertebra and absence of movement. When not present it was considered as non-union.

Statistical analysis was performed using SPSS v21¹³. Continuous variables were analysed with T-test and non-parametric equivalents as needed. Categorical variables were analysed using Qui-square. Ranawat index was converted in a numeric scale from 1 to 4 (with correspondence to the index graduation).

RESULTS

The inclusion process, as well as imagiologic indexes measured, are available on Figure 1. Demographic data and additional results are showed on Table I.

Forty-five patients followed on Rheumatology department where included (1%) and represent those with RA that were submitted to surgical management of CC affection. Their mean age was of 53.4 years. Thirty were females (vs 15 males, $p < 0.05$). Twenty-five patients presented with AAI (55.6%), 13 with CCI (28.9%), and 7 with SAI (15.6%).

Among patients with AAI, 10 were submitted to surgical procedure using wiring techniques (Brooks or Galie) and 15 with rigid methods (2 using Magerl method, 5 using Harms method and 8 with Wright). When concerning CCI, 4 patients were submitted to an occipitocervical fusion using wires, and 9 using rigid systems (plates, rods and screws). Finally, patients with SAI (n=7) were all submitted to cervical arthrodesis by

TABLE I. CHARACTERISTICS OF THE POPULATION

	CCI (n=13)	AAI (n=25)	SAI (n=7)	Total
Age at surgery	51.9 (11.5)	53.4 (11.2)	53.7 (7.4)	53.4 (10.6)
Mean Age	59.9 (11.5)	58.04 (13.8)	58.7 (9.4)	58.7 (12.3)
Male	53.8%	24.0%	28.6%	33.3%
Comorbidities	54.5%	60.9%	57.1%	58.5%
Bone Fusion	76.9%	88.0%	100%	86.7%
Re-intervention	22.2%	13%	0%	12.8%
Complications – short term	44.4%	16.4%	14.3%	23.3%
Complications – long term	7.7%	16%	14.3%	16.2%
Instability C1-C2	53.8%	100%	28.6%	86.5%
Reductible	71.4%	87%	100%	86.5%

Results presented as Mean (SD) or percent of overall sample

CCI: cranio-cervical instability; AAI: atlanto-axial instability; SAI: sub-axial instability

and anterior approach with bone graft and plate fixation. *In situ* stabilization was performed in patients with an irreducible instability (13.5% of all patients).

Bone fusion occurred in 86.7% of cases, with no significant results when comparing patients according to the type of instability. However, there is a statistically

significant difference when comparing the fusion rates according to surgical technique chosen ($p < 0.05$).

The differences in AADI, PADI and Ranawat line before and after surgery are available on Figure 1. When looking to the group with AAI and CCI instabilities, there is a significant increase in PADI and a decrease in

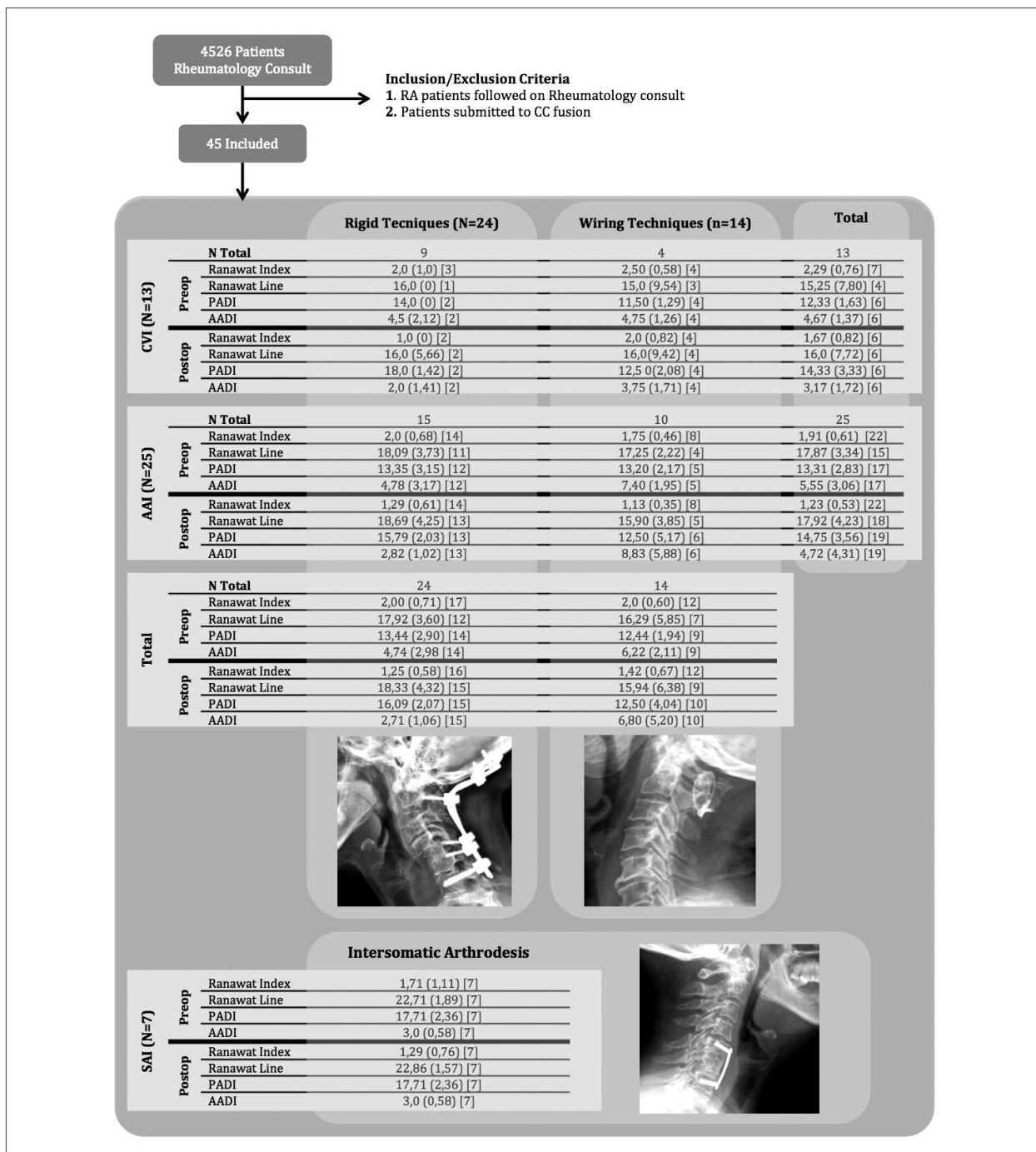


FIGURE 1. Inclusion process and measured radiographic indexes

TABLE II. RANAAT INDEX BEFORE AND AFTER SURGERY

	Ranawat Index Postoperative					
	Grade 1	Grade 2	Grade 3a	Grade 3b	Total	
Preoperative	Grade 1	10	0	0	0	10
	Grade 2	17	2	0	0	19
	Grade 3a	0	3	2	0	5
	Grade 3b	0	0	1	0	1
	Total	27	5	3	0	35

CCI: crania-cervical instability; AAI: atlanto-axial instability; SAI: sub-axial instability

AADI after surgery evaluation ($p < 0.05$). However, when patients are grouped according to the type of instability (AAI or CCI), this difference only persists in AAI group, with a positive variation in this value (mean +2.07, $p < 0.05$). When the evaluation was performed considering the type of surgery, only the rigid systems showed a significant increase in PADI and decrease in AADI ($p < 0.05$).

The Ranawat index was available in 35 patients (Table II). None of these showed a progression on neurologic score, and 60% had some kind of improvement, raising 1 or 2 degrees. In after-surgery evaluation, the number of patients showing neurologic recovery is significantly higher than those showing the same Ranawat index score ($p < 0.05$). When analyzing the subgroup of patients with AAI ($n = 22$, 68% of recoveries, $p < 0.05$) and with SAI ($n = 7$, 43% of recoveries, $p < 0.05$), both of these groups showed a significant neurologic improvement, what was not observed in patients with CCI ($n = 6$, 50% of recovery). The same tendency for a significant neurologic recovery is also present when evaluating the surgical techniques, with both rigid systems and arthrodesis techniques ($p < 0.05$). However, this improvement is not statistically significant with wiring systems. Additionally, we observed that patients with a higher pre-operative Ranawat index (3a or 3b) showed an evolution that is not significantly different from the one present in patients with less neurologic affection (Grade 1 and 2) ($p > 0.05$).

The complications rate was of 23.1% (Table I). Three occurred in the immediate post-surgical period, with 2 vertebral artery lacerations, and 1 intra-canalicular screw. Six patients were diagnosed with non-union. Five non-unions happened with less rigid systems and 1 with rigid ones ($p < 0.05$). Five of these patients had

been already submitted to revision surgery, 3 patients were treated with wiring and 2 with rigid techniques. In the last evaluation all showed bone fusion.

Additionally, there is a significant difference in the type of complications when comparing rigid with wiring systems, with the first showing more peri-operative complications and the second resulting more frequently in non-unions.

DISCUSSION

This study showed that the surgical management of RA patients with CC instability leads to a significant clinical and imagiological improvement.

When concerning the group of patients with AAI or CCI instabilities we observed a significant post-operative increase in PADI and decrease in AADI. These results were only significant in patients submitted to a rigid fixation when evaluating specific subgroups according to the type of surgery. AADI and PADI variations were also shown in previous articles, being easily understood, since the surgery aims an anatomic restoration of the vertebral relations, what leads to neurologic improvement¹⁴. When concerning the type of instability, only patients with AAI showed a significant increase in PADI ($p < 0.05$), which is also explainable by anatomic features. It is known that PADI has a strong correlation with neurologic damage, being the best predictive value in respect to neurologic improvement¹⁵. This leads to the possibility that patients submitted to rigid fixation may have better outcomes, what goes along with the better Ranawat index values achieved with rigid techniques.

Neurologic compromise is one of the most important criteria in what comes to patient's referral for

surgery¹⁶. In this study no patients with pre-operative neurologic affection showed deterioration of their neurologic state, with 60% having some kind of recovery ($p < 0.05$). Similarly, previous reports showed that conservatively treated patients have a worse prognosis, with higher mortality and lower probability of neurologic improvement¹⁷⁻²², especially those with higher Ranawat index values. Furthermore, we observed that the neurological improvement seems to be independent of the patient's initial Ranawat state, what may show that surgery can be benefic in any disease phase. However, while neurologic improvement occurs in any Ranawat grade, it is known that the sooner the patients are submitted to surgery, the better is the final outcome, since they have less pre-operative neurologic impairment, and consequently, higher odds of retrieval their full capacities^{10,20,24}. Although no patient had a decline in Ranawat index after surgery, only patients with a rigid fixation system had a significant improvement in their index ($p < 0.05$), when evaluating the type of surgery. This contrasts with previous reports showing neurologic improvement in patients submitted to wiring techniques¹⁴. However, our overall result goes along with previous statements of surgical treatment a major option for RA patients¹⁴.

Additionally, this study showed that all non-union were properly treated in revision surgery and that no death occurred as a result of the surgical procedure, what reinforces the idea that CC surgery is a relatively safe procedure and that patients should be referred to surgical treatment in earlier disease states, what is known to lead to better surgical outcomes and lower complication rates^{23,25-28}.

The number of patients included in our study was reduced, since only 1% of patients with RA followed in rheumatology outpatient clinic were proposed for cervical stabilization during the period studied. Previous works showed that around 85% of patients with RA have CC affection²⁹. This under-reference can be mainly due to a divergence of opinion as to when surgery is appropriate, since radiological progression is unpredictable and there is a poor correlation between an increasing atlanto-dens interval and the development of neurological signs^{11,15,30,31}. Another possible accounting factor the introduction of new conservative therapies such as the biologic and RA disease-modifying drugs. It was shown that these may delay the appearance of CC changes^{20,21}, but don't stop the progression of pre-existing instabilities³². Although new conservative treatments are available it is suspected that many patients

referral for surgery is delayed, what can not only compromise their quality of life, but also affect their prognosis, since presence of untreated myelopathy in patients referred for surgery accounts for a worse prognosis and outcome, with less neurologic recovery and higher death rates³³. Particularly, in patients with any kind of neurologic impairment, surgical treatment has been proved to be the only one that both prevents and reverses damage evolution^{10,34,35}. Additionally, Agarwal et al. showed that earlier surgery prevents further progression of the instability, since their series ended up with no CCI appearing after prophylactic atlantoaxial fixation in patients with AAI³⁶.

However, no consensus being available on optimal timing for surgical intervention²⁴, this study goes along with many others that showed that better neurologic outcomes can be expected if the patient is submitted to surgical treatment in earlier stages of CC affection.

In general, this study showed that CC surgical management in patients with RA is a relatively safe procedure, with a high rate of neurologic improvement. Surgical techniques should be decided in an individual approach, but our results showed that rigid techniques may have some advantages over wiring ones.

CORRESPONDENCE TO

Nuno Neves
Serviço de Ortopedia, Centro Hospitalar São João
Alameda Prof. Hernâni Monteiro 4200 Porto
Portugal
E-mail: nsmneves@gmail.com

REFERENCES

1. Moskovich R, Crockard HA, Shott S, et al. Occipitocervical stabilization for myelopathy in patients with rheumatoid arthritis. Implications of not bone-grafting. *J Bone Joint Surg Am.* 2000;82;3:349-365.
2. Linos A, Worthington JW, O'Fallon WM, et al. The epidemiology of rheumatoid arthritis in Rochester, Minnesota: a study of incidence, prevalence, and mortality. *Am J Epidemiol.* 1980;111;1:87-98.
3. Casey AT, Crockard HA, Bland JM, et al. Surgery on the rheumatoid cervical spine for the non-ambulant myelopathic patient-too much, too late? *Lancet.* 1996;347;9007:1004-1007.
4. Reiter MF, Boden SD. Inflammatory disorders of the cervical spine. *Spine (Phila Pa 1976).* 1998;23;24:2755-2766.
5. Dreyer SJ, Boden SD. Natural history of rheumatoid arthritis of the cervical spine. *Clin Orthop Relat Res.* 1999;366:98-106.
6. Bouchaud-Chabot A, Liote F. Cervical spine involvement in rheumatoid arthritis. A review. *Joint Bone Spine.* 2002;69;2:141-154.
7. Nguyen HV, Ludwig SC, Silber J, et al. Rheumatoid arthritis of the cervical spine. *Spine J.* 2004;4;3:329-334.
8. Weissman BN, Aliabadi P, Weinfeld MS, et al. Prognostic features of atlantoaxial subluxation in rheumatoid arthritis patients. *Radiology.* 1982;144;4:745-751.

9. Neo M. Treatment of upper cervical spine involvement in rheumatoid arthritis patients. *Mod Rheumatol*. 2008;18;4:327-335.
10. Kraus DR, Peppelman WC, Agarwal AK, et al. Incidence of subaxial subluxation in patients with generalized rheumatoid arthritis who have had previous occipital cervical fusions. *Spine (Phila Pa 1976)*. 1991;16;10 Suppl:S486-489.
11. Pellicci PM, Ranawat CS, Tsairis P, et al. A prospective study of the progression of rheumatoid arthritis of the cervical spine. *J Bone Joint Surg Am*. 1981;63;3:342-350.
12. Ranawat CS, O'Leary P, Pellicci P, et al. Cervical fusion in rheumatoid arthritis. *J Bone Joint Surg Am*. 1979; 61:1003-1010
13. IBM Corp. Released 2012. IBM SPSS Statistics for Windows, Version 21.0. Armonk, NY: IBM Corp.
14. Heywood AW, Learmonth ID, Thomas M. Cervical spine instability in rheumatoid arthritis. *J Bone Joint Surg Br*. 1988;70;5:702-707.
15. Boden SD, Dodge LD, Bohlman HH, et al. Rheumatoid arthritis of the cervical spine. A long-term analysis with predictors of paralysis and recovery. *J Bone Joint Surg Am*. 1993;75;9:1282--1297.
16. Borenstein D. Inflammatory arthritides of the spine: surgical versus nonsurgical treatment. *Clin Orthop Relat Res*. 2006;443:208-221.
17. Casey AT, Crockard HA, Bland JM, et al. Predictors of outcome in the quadriparetic nonambulatory myelopathic patient with rheumatoid arthritis: a prospective study of 55 surgically treated Ranawat class IIIb patients. *J Neurosurg*. 1996;85;4:574-581.
18. Marks JS, Sharp J. Rheumatoid cervical myelopathy. *Q J Med*. 1981;50;199:307-319.
19. Meijers KA, van Beusekom GT, Luyendijk W, et al. Dislocation of the cervical spine with cord compression in rheumatoid arthritis. *J Bone Joint Surg Br*. 1974;56-B;4:668-680.
20. Mori T, Matsunaga S, Sunahara N, et al. 3- to 11-year followup of occipitocervical fusion for rheumatoid arthritis. *Clin Orthop Relat Res*. 1998;351:169-179.
21. Omura K, Hukuda S, Katsuura A, et al. Evaluation of posterior long fusion versus conservative treatment for the progressive rheumatoid cervical spine. *Spine (Phila Pa 1976)*. 2002;27;12:1336-1345.
22. Sunahara N, Matsunaga S, Mori T, et al. Clinical course of conservatively managed rheumatoid arthritis patients with myelopathy. *Spine (Phila Pa 1976)*. 1997;22;22:2603-7; discussion 8.
23. Zoma A, Sturrock RD, Fisher WD, et al. Surgical stabilisation of the rheumatoid cervical spine. A review of indications and results. *J Bone Joint Surg Br*. 1987;69;1:8-12.
24. Wolfs JF, Kloppenburg M, Fehlings MG, et al. Neurologic outcome of surgical and conservative treatment of rheumatoid cervical spine subluxation: a systematic review. *Arthritis Rheum*. 2009;61;12:1743-1752.
25. Grob D. Atlantoaxial immobilization in rheumatoid arthritis: a prophylactic procedure? *Eur Spine J*. 2000;9;5:404-409.
26. Hamilton JD, Gordon MM, McInnes IB, et al. Improved medical and surgical management of cervical spine disease in patients with rheumatoid arthritis over 10 years. *Ann Rheum Dis*. 2000;59;6:434-438.
27. McRorie ER, McLoughlin P, Russell T, et al. Cervical spine surgery in patients with rheumatoid arthritis: an appraisal. *Ann Rheum Dis*. 1996;55;2:99-104.
28. Mizutani J, Tsubouchi S, Fukuoka M, et al. Surgical treatment of the rheumatoid cervical spine in patients aged 70 years or older. *Rheumatology (Oxford)*. 2002;41;8:910-916.
29. Shen FH, Samartzis D, Jenis LG, et al. Rheumatoid arthritis: evaluation and surgical management of the cervical spine. *Spine J*. 2004;4;6:689-700.
30. Mathews JA. Atlanto-axial subluxation in rheumatoid arthritis. A 5-year follow-up study. *Ann Rheum Dis*. 1974;33;6:526-531.
31. Rana NA. Natural history of atlanto-axial subluxation in rheumatoid arthritis. *Spine (Phila Pa 1976)*. 1989;14;10:1054-1056.
32. Kaito T, Hosono N, Ohshima S, et al. Effect of biological agents on cervical spine lesions in rheumatoid arthritis. *Spine (Phila Pa 1976)*. 2012;37;20:1742-1746.
33. Matsunaga S, Sakou T, Onishi T, et al. Prognosis of patients with upper cervical lesions caused by rheumatoid arthritis: comparison of occipitocervical fusion between c1 laminectomy and nonsurgical management. *Spine (Phila Pa 1976)*. 2003;28;14:1581-7; discussion 7.
34. Santavirta S, Konttinen YT, Laasonen E, et al. Ten-year results of operations for rheumatoid cervical spine disorders. *J Bone Joint Surg Br*. 1991;73;1:116-120.
35. Santavirta S, Slati P, Kankaanpaa U, et al. Treatment of the cervical spine in rheumatoid arthritis. *J Bone Joint Surg Am*. 1988;70;5:658-667.
36. Agarwal AK, Peppelman WC, Kraus DR, et al. Recurrence of cervical spine instability in rheumatoid arthritis following previous fusion: can disease progression be prevented by early surgery? *J Rheumatol*. 1992;19;9:1364-1370.