

IMAGES IN RHEUMATOLOGY

Thyroid membrane involvement in rheumatoid nodules: a rare finding

Dias JI¹, Pereira AI², Sousa FA¹, Sousa e Castro S¹, Meireles L¹

A 76-year-old woman with a 19-year history of rheumatoid arthritis (RA) and elevated anti-CCP antibodies presented with progressive constitutional symptoms, including cachexia, over the past two years. The patient denied dysphagia and dyspnea. Her medical history was notable for depressive and anxiety disorders, as well as recent cognitive deterioration.

A cervical CT-scan revealed a suspicious lesion in left

thyroid membrane, raising concerns for malignancy (Figure 1). A subsequent PET-scan identified a hypermetabolic nodular lesion in the cervical region, specifically in the vallecula, slightly left of the midline. No hypermetabolic malignant adenopathies were found.

Due to the strong suspicion of malignancy, the patient underwent cervicotomy for excision of the lesion. Histopathological examination revealed the nodule to be a rheumatoid nodule, consistent with the granulomatous inflammation typically seen in RA. Tuberculosis screening was negative.

A follow-up cervical CT scan confirmed complete excision of the lesion. The patient's cachexia and constitutional symptoms were ultimately attributed to her underlying autoimmune disease and cognitive decline.

¹ Department of Otorhinolaryngology and Head and Neck Surgery, Unidade Local de Saúde de Santo António, Porto, Portugal

² Department of Neuroradiology, Unidade Local de Saúde de Santo António, Porto, Portugal

Submitted: 14/10/2024

Accepted: 26/12/2024

Correspondence to Joana Ida Sousa Dias
E-mail: joanaidasousadias@gmail.com

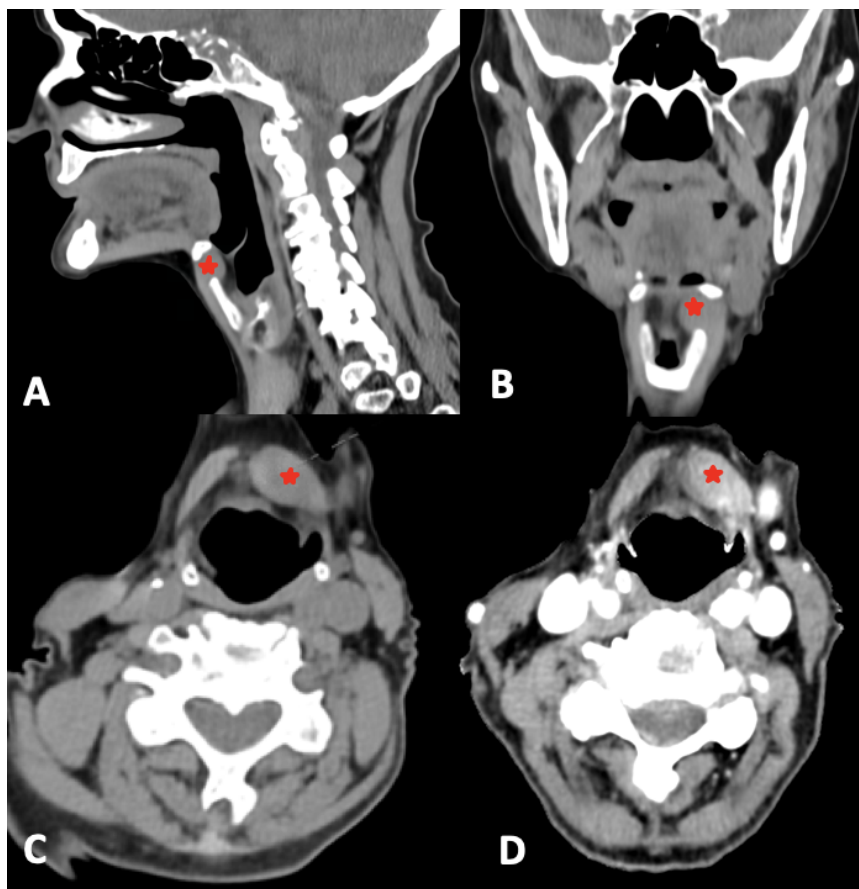


Figure 1. CT scan of the neck, sagittal (A), coronal (B) and axial (C) views show an ovoid lesion (*) in the left thyroid membrane, located strictly in the submucosal layer, with slight deformation of the vallecula and contrast enhancement (D)

DISCUSSION

Rheumatoid nodules are a common extra-articular manifestation of RA, usually found in subcutaneous pressure areas like the elbows and fingers¹. Involvement of deeper structures, such as the thyroid membrane or the pre-epiglottic region, is exceedingly rare, with few cases documented in the literature^{2,3,4}.

Our case emphasizes the importance of considering rheumatoid nodules in the differential diagnosis of cervical masses in patients with long-standing RA. Early identification can prevent unnecessary surgical interventions and guide appropriate management. The pathogenesis of rheumatoid nodules involves immune complex deposition and fibrinoid necrosis, though their formation in atypical sites remains poorly understood⁵.

REFERENCES

1. Bang S, Kim Y, Jang K, Paik SS, Shin SJ. Clinicopathologic features of rheumatoid nodules: a retrospective analysis. *Clin Rheumatol*. 2019 Nov;38(11):3041-3048. Epub 2019 Jul 4. PMID: 31273637. <https://doi.org/10.1007/s10067-019-04668-1>
2. Bhargava A, Hegde PU, Tallapureddy S, Varghese S, Forouhar FA, Tendler BE. Rheumatoid nodules in the thyroid bed following total thyroidectomy: a case report. *J Med Case Rep*. 2013 Oct 29;7:247. PMID: 24168730; PMCID: PMC3843512. <https://doi.org/10.1186/1752-1947-7-247>
3. Sivridis E, Kouroupi M, Koukourakis MI, Arelaki S, Lyratzopoulos N, Giatromanolaki A. Rheumatoid nodules in thyroid gland parenchyma as an expression of rheumatoid arthritis: a case report. *J Med Case Rep*. 2019 May 28;13(1):159. PMID: 31133043; PMCID: PMC6537448. <https://doi.org/10.1186/s13256-019-2113-9>
4. Martins S, Fernandes BM, Bernardes M, Melo D, Neto T. Rheumatoid Nodule Simulating a Parotid Tumor. *Head Neck Pathol*. 2021 Mar;15(1):334-340. Epub 2020 May 20. PMID: 32436170; PMCID: PMC8010028. <https://doi.org/10.1007/s12105-020-01175-7>
5. Fareez F, Moodley J, Popovic S, Lu JQ. Rheumatoid nodules: a narrative review of histopathological progression and diagnostic consideration. *Clin Rheumatol*. 2023 Jul;42(7):1753-1765. Epub 2023 Mar 29. PMID: 36991243. <https://doi.org/10.1007/s10067-023-06589-6>