

LETTERS TO THE EDITOR

Drugs and ANCA – an atypical association

Beirão T¹, Samões B¹, Rua C¹, Vieira R¹, Abelha-Aleixo J¹, Pinto P¹, Costa F¹, Fonseca D¹, Mota M², Amorim Meireles C³, Videira T¹

Dear editor,

Eosinophilic vasculitis is a rare condition due to vascular damage and infiltration of eosinophils into tissues¹. Antineutrophil cytoplasmic antibody (ANCA), like perinuclear ANCA (p-ANCA), is common in the context of systemic vasculitis, but its association with illicit drug use is unusual². This case report showcases a distinctive scenario featuring a positive pANCA, prompting a meticulous examination of the interplay between vasculitic manifestations and drug abuse.

A 35-year-old man presented progressive nasal obstruction, epistaxis, and septal deformity, with no systemic complaints. The patient denied drug abuse. Physical examination revealed bilateral nasal crust and septal perforation and facial CT confirmed septal perforation (Figure 1A). Laboratory evaluation revealed markers of inflammation (PCR 1.08mg/dL), eosinophilia (780/uL - 10.8%) and a positive 1/640 p-ANCA test, with negative anti-MPO and anti-PR3. Nasal biopsy confirmed eosinophilic vasculitis (Figure 1B) septal destruction (Figure 1C) and inflammation with proliferation of B and T lymphocytes (Figure 1D), no evidence of granulomas, with positive cultures for *Aspergillus fumigatus*. Imaging studies revealed no evidence of systemic vasculitis. Based on the clinical presentation, laboratory tests, and biopsy results, the diagnosis of p-ANCA positive eosinophilic vasculitis with aspergillus infection was made. The patient was initially treated with voriconazole 200mg bid initially, with partial clinical response. Only at the third appointment, the patient admitted having a chronic habit of inhaled cocaine use. Later, refused going to a detox program and immunosuppressive therapy and decline further treatment, with loss of follow-up.

Cocaine induced vasculitis may be difficult to distin-

guish from idiopathic AAV³. Careful assessment of clinical, histological and serological patterns is required. Both cocaine induced vasculitis and idiopathic AAV can lead to sino-nasal destruction due to necrosis and inflammation, which can be clinically indistinguishable. However, cocaine induced disease is usually associated with localised rather than multi-system involvement⁴, like this case. It is worth mention that, in case of destruction of nasal columella and upper lip, it is highly suggestive of cocaine induced disease, since it is not a feature of idiopathic AAV. Histological patterns of cocaine induced vasculitis can also help differentiate, since there is absence of hallmarks of granulomatosis with polyangiitis, such as granulomas⁴, which were absent in this case report's biopsy.

Although ANCA positivity is reported in over 50% of patients with cocaine use, the pattern is usually atypical and may test positive for both MPO and PR3⁴. Our patient presented a positive 1/640 p-ANCA test, with negative anti-MPO and anti-PR3. This showcases the importance of a comprehensive drug history, despite a positive ANCA test. The detection of human Neutrophil Elastase (HNE) antibodies offers an additional diagnosis tool. HNE antibodies have not been linked to idiopathic AAV, but with cocaine-induced vasculitis⁵. Our centre did not have access to the HNE assay.

Management of cocaine-induced vasculitis is based on discontinuation of cocaine use and appropriate medical therapy. On most cases, low-dose prednisolone, along with wound measures, are sufficient to promote healing and aiding symptom control⁶. However, in some cases, DMARDs are necessary, being methotrexate the most commonly used⁶. The potential for relapse remains significant, showcasing the necessity of addressing the underlying substance abuse disorder⁶.

Aspergillus fumigatus is a common environmental fungus⁷. It releases spores into the air which, when inhaled, can cause respiratory tract infections in individuals with compromised immune systems. The fungus can also invade blood vessels, triggering an immune response characterized by an accumulation of eosinophils⁷. To the best of our knowledge, no case of linked eosinophilic vasculitis and aspergillus infection has been described. Voriconazole was used to treat the aspergillus infection.

¹ Rheumatology Department, Centro Hospitalar de Vila Nova de Gaia e Espinho, Vila Nova de Gaia; ² Internal Medicine Department, Centro Hospitalar de Vila Nova de Gaia e Espinho, Vila Nova de Gaia; ³ Surgical Pathology Department, Centro Hospitalar de Vila Nova de Gaia e Espinho, Vila Nova de Gaia

Submitted: 21/12/2023

Accepted: 01/07/2024

Correspondence to: Tiago Beirão
E-mail: tiagobeirao11@gmail.com

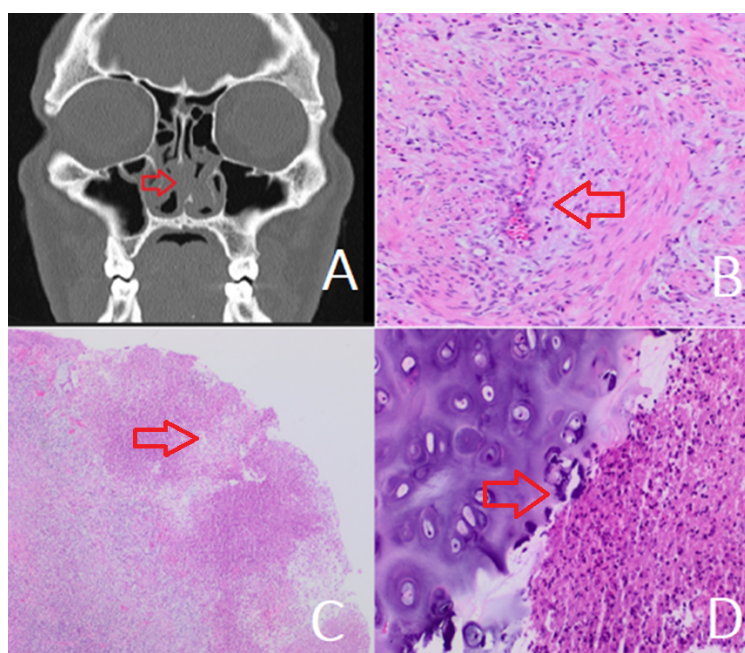


Figure 1. (A) Patients' facial CT confirming septal perforation; Nasal biopsy confirmed eosinophilic vasculitis (B - H&E, 100X) septal destruction (C - H&E, 20x) and inflammation with proliferation of B and T lymphocytes (D - H&E, 100x)

In conclusion, this case report underlines the significance of exploring potential triggers and complications in patients with eosinophilic vasculitis. Clinicians should be vigilant about the association between drug abuse and vasculitic syndromes. Timely diagnosis, aggressive management, and cessation of illicit drug use, along with prompt antifungal therapy in cases of superinfection, are essential to achieve a successful outcome in such patients.

REFERENCES

1. Cottin V. Eosinophilic Lung Diseases. *Immunol Allergy Clin North Am.* 2023, 43:289-322. <https://doi.org/10.1016/j.iac.2023.01.002>
2. Yaseen K, Nevares A, Tamaki H. A Spotlight on Drug-Induced Vasculitis. *Curr Rheumatol Rep.* 2022, 24:323-336. <https://doi.org/10.1007/s11926-022-01088-0>
3. Graf J. Rheumatic manifestations of cocaine use. *Curr Opin Rheumatol.* 2013, 25:50-55. <https://doi.org/10.1097/BOR.0b013e32835b4449>
4. Trimarchi M, Gregorini G, Facchetti F, et al. Cocaine-induced midline destructive lesions: clinical, radiographic, histopathologic, and serologic features and their differentiation from Wegener granulomatosis. *Medicine (Baltimore).* 2001, 80:391-404. <https://doi.org/10.1097/00005792-200111000-00005>
5. Wiesner O, Russell KA, Lee AS, et al. Antineutrophil cytoplasmic antibodies reacting with human neutrophil elastase as a diagnostic marker for cocaine-induced midline destructive lesions but not autoimmune vasculitis. *Arthritis Rheum.* 2004, 50:2954-2965. 10. <https://doi.org/10.1002/art.20479>
6. Subesinghe S, van Leuven S, Yalakki L, Sangle S, D'Cruz D. Cocaine and ANCA associated vasculitis-like syndromes - A case series. *Autoimmun Rev.* 2018, 17:73-77. <https://doi.org/10.1016/j.autrev.2017.11.011>
7. van de Veerdonk FL, Gresnigt MS, Romani L, Netea MG, Latge JP: *Aspergillus fumigatus* morphology and dynamic host interactions. *Nat Rev Microbiol.* 2017, 15:661-674. <https://doi.org/10.1038/nrmicro.2017.90>