

CASE BASED REVIEWS

Ferric carboxymaltose-induced hypophosphatemia – a case series

Campinho Ferreira C¹ , Pereira P¹, Correira M¹, Costa E¹, Esperança Almeida D¹, Redondo Costa J¹, Roxo Ribeiro A¹, Leite Silva J¹

ABSTRACT

Hypophosphatemia may cause serious complications. Depending on its severity and duration, signs and symptoms range from fatigue to life-threatening events, like severe rhabdomyolysis and mental status changes. Long-term consequences include osteomalacia. Hypophosphatemia may be secondary to the use of parental iron, mostly associated with ferric carboxymaltose (FCM), with an incidence of around 45% to 70%. We describe three cases of hypophosphatemia in patients with chronic iron deficiency anemia, requiring repeated FCM infusions. The patients' presentation to the Rheumatology department included musculoskeletal symptoms of severe hypophosphatemia and long-term hypophosphatemic osteomalacia, with fractures. We aim to raise awareness for ferric carboxymaltose-induced hypophosphatemia, an entity increasingly described in the literature that can be responsible for severe disability or potentially life-threatening adverse events.

Keywords: Osteomalacia; Ferric carboxymaltose; Drug-induced rheumatic disease; Hypophosphatemia; Adverse event.

INTRODUCTION

Phosphorus plays an essential role in human metabolism, acting as an enzyme cofactor, and being part of many cellular processes. It is also indispensable for hydroxyapatite crystals formation, which is fundamental for the mechanical strength of mineralized tissues. Normal phosphorus plasma levels range between 2.5 and 4.5 mg/dl with tight regulation occurring in the renal proximal tubule, where 85 to 90% of filtered phosphorus is reabsorbed. The key regulators of phosphorus homeostasis are fibroblast growth factor 23 (FGF23), parathormone (PTH), and vitamin D¹⁻³. Disturbances in phosphorus levels may have deleterious effects in both the short and long term⁴.

Iron deficiency is the main cause of anemia⁵. Even though oral iron supplementation is the first-line treatment choice for iron deficiency anemia it may not be effective due to poor gastrointestinal tolerability or absorption^{1,6}. Parental iron formulations have been increasingly used, promoting a quicker and better correc-

tion of the iron deficit^{6,7}. Despite its good tolerability and safety, some adverse events have been described, namely the emergence of hypophosphatemia^{4,8}. Hypophosphatemia secondary to parental iron is mostly associated with ferric carboxymaltose (FCM)^{4,9}, with an incidence of around 45%⁹ to 70%¹⁰. The mechanism responsible for FCM-associated hypophosphatemia is not fully understood. It is thought that FCM leads to an increase in FGF23 levels^{1,8} and consequently to an increase in renal phosphorus excretion. Besides its phosphaturic effects, FGF23 also causes inhibition of vitamin D activation, hypocalcemia, and secondary hyperparathyroidism, which perpetuates the phosphaturic effect^{2,8}. Interestingly, the rate of hypophosphatemia after FCM treatment is significantly decreased in chronic kidney disease patients, with an incidence of about 27%. The reduction in glomerular filtration rate impairs urinary phosphate excretion and may partially protect against the development of hypophosphatemia^{11,12}. When symptoms occur, patients with FCM-associated hypophosphatemia may experience bone pain, fatigue, and weakness and they can develop rhabdomyolysis and osteomalacia^{1,8,11}.

Our work describes 3 patients with hypophosphatemia associated with long-term treatment with FCM, presenting musculoskeletal symptoms and atraumatic fractures. All of them improved after supplementation with calcium, phosphorus, and vitamin D and switching of the iron formulation to saccharated ferric oxide.

¹ Rheumatology Department, Unidade Local de Saúde de Braga, Braga, Portugal

Submitted: 22/02/2024

Accepted: 07/04/2024

Correspondence to Carla Campinho Ferreira
E-mail: carla.campinho.95@gmail.com

CASE REPORT

Case 1: A 57-year-old female was admitted to the outpatient clinic for sudden atraumatic disabling foot pain evolving for 2 weeks, refractory to treatment with nonsteroidal anti-inflammatory drugs. She had a diagnosis of Rendu-Osler-Weber syndrome conditioning chronic iron-deficiency anemia and requiring multiple infusions of FCM (cumulative dose of 12g) and red blood cell transfusions in the previous 3 years. Right foot plain X-ray revealed a 2nd metatarsal bone fracture (Figure 1). Hypophosphatemia (1,2 mg/dL), vitamin D deficiency (2.3 µg/dl), increased alkaline phosphatase

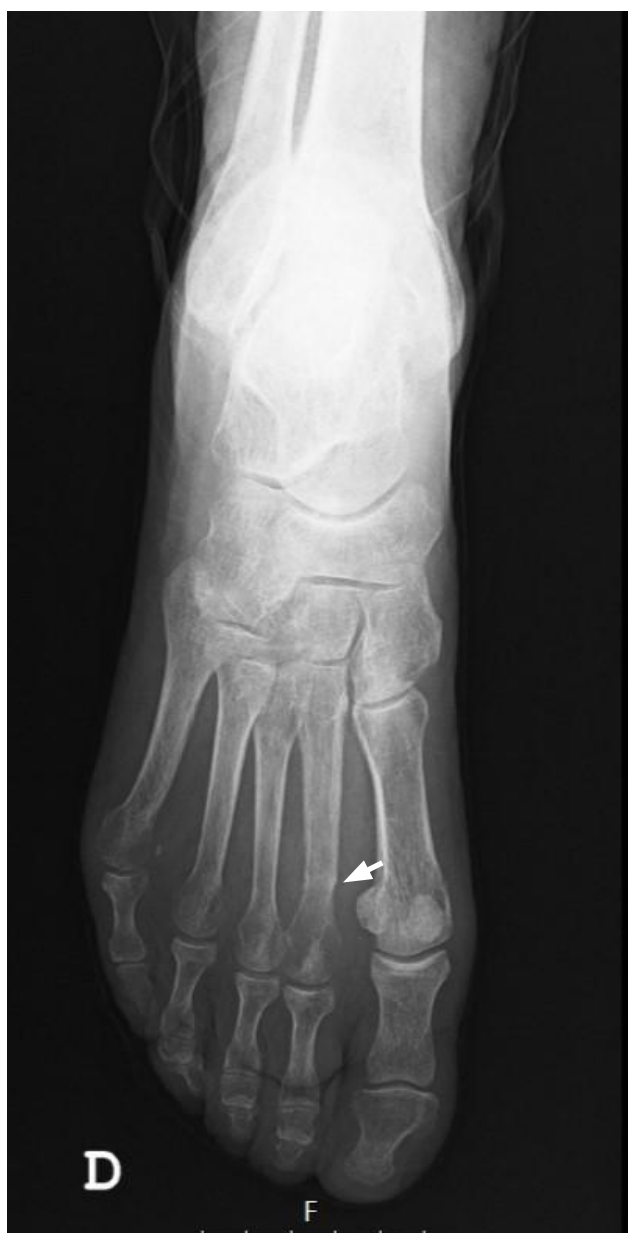

Figure 1. Right foot plain X-ray revealing a 2nd metatarsal bone fracture (white arrow).

[AF (23 U/dl)] and PTH (9.45 ng/dl) levels, and normal calcium levels were revealed in the blood tests. Supplementation with calcifediol 2.266mg every 3 weeks, and a multivitamin with phosphorus was started and the patient was instructed to increase daily milk ingestion by up to one liter. Due to suspicion of hypophosphatemic osteomalacia associated with FCM treatment, the iron formulation was replaced by saccharated ferric oxide. After 1-year follow-up, the patient was no longer on phosphorus supplementation, had no new fractures, and exhibited normal values of calcium, phosphorus, and vitamin D (Figure 2).

Case 2: A 73-year-old male was admitted to the rheumatology outpatient clinic due to muscle aches and lower limb weakness for 18 months, requiring the use of a wheelchair. Previous history was relevant for the presence of Rendu-Osler-Weber syndrome treated with octreotide, and several infusions of FCM (cumulative dose of 27g) in the previous 10 years. A CT scan ruled out lumbar spinal stenosis or radiculopathy. Blood tests revealed severe hypophosphatemia (0.9 mg/dl), vitamin D deficiency (2.8 µg/dl), increased AF (23.6 U/dl) and PTH (18.717 ng/dl) levels, and normal calcium levels. Bone densitometry revealed a lumbar spine T-score of -3.0 and a femoral neck T-score of -4.4. Phosphorus (maximum dose 515.7 mg daily), calcium (2000 mg daily), and calcitriol (0.25 µg daily) supplementation were started, and the iron formulation was switched to saccharated ferric oxide. After 4 months, phosphorus and vitamin D levels normalized (Figure 2), and the patient gradually recovered. He is currently on 2000 mg of calcium, 0.25 µg of calcitriol, and 345 mg of phosphorus per day.

Case 3: A 74-year-old man was assessed in the rheumatology outpatient clinic for generalized arthralgias, joint stiffness, pleuritic chest pain, and inability to walk independently, for 6 months. He had a history of Crohn's disease, idiopathic chronic liver disease complicated with portal hypertension and esophageal varices, and multifactorial anemia requiring multiple red blood cell transfusions (total of 130 units) and FCM supplementation (cumulative dose of 23 g) in the previous 7 years. Physical examination was unremarkable for the presence of arthritis or muscle strength deficit. Blood samples revealed microcytic hypochromic anemia (hemoglobin 7.6 g/dl), hypophosphatemia (1.3 mg/dl), and normal calcium, vitamin D, PTH, and AF levels. A positron emission tomography was performed which revealed a slight uptake in the 5th to 8th right costal arches and in the 6th to 8th left costal arches, favoring the diagnosis of fractures. There was no history of trauma. Bone densitometry revealed a lumbar spine T-score of -3.2 and a femoral neck T-score of -3.3. The diagnosis of hypophosphatemic osteomalacia was made

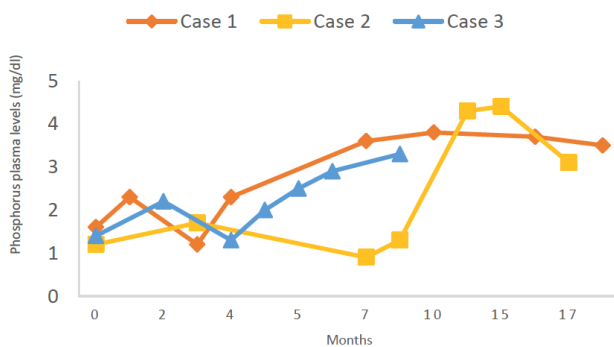


Figure 2. Serial changes in phosphorus plasma levels. The arrows below indicate the timing of the increase in milk ingestion for case 1 (orange) and phosphorus supplementation for cases 2 and 3 (yellow and blue).

and the patient was started on phosphorus supplementation (maximum dose of 343.8 mg daily), maintained vitamin D supplementation (22 400 UI every 2 weeks), and the iron formulation was switched to saccharated ferric oxide. After six months, the patient regained his autonomy and now can walk without assistance and drive. He is now on 115 mg of phosphorus per day and 0.266 mg of calcifediol monthly.

DISCUSSION

FCM-associated hypophosphatemia has been increasingly recognized as an important adverse event of this treatment.

Hypophosphatemia is usually transient and asymptomatic, so its prevalence is difficult to estimate¹. However, in some cases, it can be severe, symptomatic, and persistent^{11,13}. Initial symptoms are usually nonspecific, such as generalized weakness and fatigue, leading to a significant delay in diagnosis^{1,8}. Cases 2 and 3 provide examples of this presentation, with patients complaining of muscle weakness with inability to perform activities of daily living for several months. Awareness and specific investigation of this condition allowed diagnosis of severe hypophosphatemia.

All three patients had a history of multiple previous treatments with FCM. This is the iron formulation most commonly associated with hypophosphatemia^{4,9}. Clinical presentations and incidence rates described in the literature are heterogeneous. This fact may be explained by differences in (1) the patients' underlying conditions and comorbidities, including renal function; (2) the severity of the iron deficiency; (3) the cumulative dose of FCM administered, and (4) the timing of phosphorus measurement. Most studies have few weeks of follow-up and the consequence of repeated

FCM doses on serum phosphorus levels is not commonly assessed⁴. FCM-associated hypophosphatemia may persist beyond 5 weeks after the infusion in about 29% of patients^{10,11}. Phosphorus levels may not return to the normal range before the next infusion and lead to a progressive worsening of hypophosphatemia when repeated doses of FCM are administered⁴. Furthermore, a randomized clinical trial showed that most of the patients treated with FCM had recovered from hypophosphatemia by day 70 of follow-up, but bone AF remained elevated. These results suggest that the cascade of biochemical changes associated with increased FGF23 can persist longer⁹.

Chronic hypophosphatemia may also present with bone pain and hypophosphatemic osteomalacia. Osteomalacia manifests with pseudo-fractures, which are the radiological hallmark of the disease and may progress to complete fractures, and bone pain¹⁴. In cases 1 and 3, patients presented with atraumatic persistent bone pain that ultimately led to the diagnosis of metatarsal and rib fractures. A systematic review identified 30 clinical cases of osteomalacia associated with repeated iron infusions. Most patients (62%) had been treated with FCM. In this review, 93% of the patients had received more than 5 infusions. It may be hypothesized that persistent and prolonged hypophosphatemia is probably necessary for the development of osteomalacia¹⁴.

Widespread recommendations on the treatment of hypophosphatemia suggest supplementation with active vitamin D and phosphorus^{4,8}. However, in most cases of FCM-associated hypophosphatemia, supplementation is not sufficient, and it is necessary to withdraw or switch the iron formulation^{14,15}. In our cases, both actions were taken simultaneously. All three patients switched their iron formulation to saccharated ferric oxide and were on calcifediol and phosphorus supplementation. In one case, the increase in phosphorus was reached by increasing dairy product intake, which is rich in phosphorus. This therapeutic measure was taken due to the sparse availability of supplements containing phosphorus.¹⁶ All patients had progressive improvement in serum phosphorus levels, reaching normal values, that coincided with the resolution of weakness and fatigue symptoms. To date, there is not enough data available on the effects of changing the iron formulation on long-term outcomes. There are also some reports of hypophosphatemia associated with saccharated ferric oxide infusions, although this is much less frequent^{10,14}.

Albeit bone densitometry performed in cases 2 and 3 was compatible with osteoporosis, anti-osteoporotic therapy was not initiated in any of the cases. There are small case reports describing the harmful effects of antiresorptive agents (bisphosphonates¹⁷⁻¹⁹ and Denosumab²⁰) in pa-

tients with osteomalacia. These treatments were associated with decreased calcium and phosphorus levels^{17,20} and increased risk of fractures, disability, and weakness^{17,18}.

Some risk factors for the development of FCM-associated hypophosphatemia have been already identified. These included intestinal malabsorption, vitamin D deficiency, and hyperparathyroidism^{14,21}. In a systematic review of case reports with hypophosphatemic osteomalacia, most of the patients had a history of gastrointestinal disease¹⁴. Intestinal malabsorption resulting from inflammatory bowel disease, as in case 3, causes a decrease in phosphorus, calcium, and vitamin D intestinal absorption, increasing the risk of hypophosphatemia. Reduced levels of calcium and vitamin D lead to an increase in PTH (secondary hyperparathyroidism), which has phosphaturic effects and can exacerbate hypophosphatemia^{1,8}.

Despite being a widely described adverse event that was recently included in the FCM label, the diagnosis of symptomatic hypophosphatemia may still be missed or significantly delayed in many patients. Some authors suggest that patients (1) presenting with musculoskeletal symptoms⁸; (2) having repeated infusions of FCM²², and; (3) having pre-existing risk factors for hypophosphatemia should be monitored for phosphorus levels before additional doses are administered⁸. Moreover, for patients with chronic hypophosphatemia, the evaluation for repeated FCM infusions should be reassessed²². A safe time interval between FCM infusion is, to date, unknown.

The most common blood test abnormalities in hypophosphatemic osteomalacia are a decrease in phosphorus and vitamin D levels and an increase in PTH and AF. However, there are some cases of patients with normal AF levels, as in those with malabsorption¹⁴.

Hypophosphatemia is a common consequence of treatments with FCM. It can result in sudden major symptoms and disability that require prompt therapeutic interventions. Hypophosphatemic osteomalacia is a somewhat chronic consequence of prolonged hypophosphatemia and it presents with bone pain and fractures. Awareness of these presentations in patients receiving chronic intravenous iron supplementation is crucial as an early diagnosis may avoid potentially serious complications. More studies are needed to clarify the long-term consequences of FCM-associated hypophosphatemia (particularly in patients with multiple infusions) and its best management.

REFERENCES

- Kalantar-Zadeh K, Ganz T, Trumbo H, Seid MH, Goodnough LT, Levine MA. Parenteral iron therapy and phosphorus homeostasis: A review. *Am J Hematol* 2021;96(5):606-616. <https://doi.org/10.1002/ajh.26100>
- Goretti Penido M, Alon US. Phosphate homeostasis and its role in bone health. *Pediatr Nephrol* 2012;27(11):2039-2048. <https://doi.org/10.1007/s00467-012-2175-z>
- Amanzadeh J, Reilly RF, Jr. Hypophosphatemia: an evidence-based approach to its clinical consequences and management. *Nat Clin Pract Nephrol* 2006;2(3):136-48. <https://doi.org/10.1038/ncpneph0124>
- Glaspy JA, Lim-Watson MZ, Libre MA, et al. Hypophosphatemia Associated with Intravenous Iron Therapies for Iron Deficiency Anemia: A Systematic Literature Review. *Ther Clin Risk Manag* 2020;16:245-259. <https://doi.org/10.2147/TCRM.S243462>
- The global prevalence of anaemia in 2011. World Health Organization. September 2015. <https://www.who.int/publications/item/9789241564960>. Accessed in January 10th 2024
- Pasricha SR, Tye-Din J, Muckenthaler MU, Swinkels DW. Iron deficiency. *Lancet* 2021;397(10270):233-248. [https://doi.org/10.1016/S0140-6736\(20\)32594-0](https://doi.org/10.1016/S0140-6736(20)32594-0)
- Van Wyck DB, Mangione A, Morrison J, Hadley PE, Jehle JA, Goodnough LT. BLOOD MANAGEMENT: Large-dose intravenous ferric carboxymaltose injection for iron deficiency anemia in heavy uterine bleeding: a randomized, controlled trial. *Transfusion* 2009;49(12):2719-2728. <https://doi.org/10.1111/j.1537-2995.2009.02327.x>
- Schaefer B, Tobiasch M, Wagner S, et al. Hypophosphatemia after intravenous iron therapy: Comprehensive review of clinical findings and recommendations for management. *Bone* 2022;154:116202. <https://doi.org/10.1016/j.bone.2021.116202>
- Rosano G, Schiefke I, Göhring UM, Fabien V, Bonassi S, Stein J. A Pooled Analysis of Serum Phosphate Measurements and Potential Hypophosphatemia Events in 45 Interventional Trials with Ferric Carboxymaltose. *J Clin Med* 2020;9(11) <https://doi.org/10.3390/jcm9113587>
- Glaspy JA, Wolf M, Strauss WE. Intravenous Iron-Induced Hypophosphatemia: An Emerging Syndrome. *Adv Ther* 2021;38(7):3531-3549. <https://doi.org/10.1007/s12325-021-01770-2>
- Schaefer B, Tobiasch M, Viveiros A, et al. Hypophosphatemia after treatment of iron deficiency with intravenous ferric carboxymaltose or iron isomaltoside-a systematic review and meta-analysis. *Br J Clin Pharmacol* 2021;87(5):2256-2273. <https://doi.org/10.1111/bcp.14643>
- Wolf M, Rubin J, Achebe M, et al. Effects of Iron Isomaltoside vs Ferric Carboxymaltose on Hypophosphatemia in Iron-Deficiency Anemia: Two Randomized Clinical Trials. *Jama* 2020;323(5):432-443. <https://doi.org/10.1001/jama.2019.22450>
- Fragkos KC, Sehgal V, Rogers J, et al. Hypophosphatemia after intravenous iron therapy with ferric carboxymaltose-Real world experience from a tertiary centre in the UK. *GastroHep* 2020;2(5):205-214. <https://doi.org/10.1002/ygh2.415>
- Vilaca T, Velmurugan N, Smith C, Abrahamsen B, Eastell R. Osteomalacia as a Complication of Intravenous Iron Infusion: A Systematic Review of Case Reports. *J Bone Miner Res* 2022;37(6):1188-1199. <https://doi.org/10.1002/jbmr.4558>
- Urbina T, Belkhir R, Rossi G, et al. Iron Supplementation-Induced Phosphaturic Osteomalacia: FGF23 is the Culprit. *Journal of Bone and Mineral Research* 2017;33(3):540-542. <https://doi.org/10.1002/jbmr.3369>
- Abridged List Ordered by Nutrient Content in Household Measure. United States Department of Agriculture. 2018. <https://www.nal.usda.gov/sites/www.nal.usda.gov/files/phosphorus.pdf>. Accessed in March 29th 2024.
- Cundy T, Que L, Hassan IM, Hughes L. Bisphosphonate-Induced Deterioration of Osteomalacia in Undiagnosed Adult Fanconi Syndrome. *JBM Plus* 2020;4(8):e10374. <https://doi.org/10.1002/jbm4.10374>

18. Rosen CJ, Brown S. Severe hypocalcemia after intravenous bisphosphonate therapy in occult vitamin D deficiency. *N Engl J Med* 2003;348(15):1503-4.
<https://doi.org/10.1056/NEJM200304103481521>
19. Collazo-Clavell ML, Jimenez A, Hodgson SF, Sarr MG. Osteomalacia after Roux-en-Y gastric bypass. *Endocr Pract* 2004;10(3):195-8. <https://doi.org/10.4158/EP.10.3.195>
20. Lin M, Ganda K. Treating 'osteoporosis': a near miss in an unusual case of FGF-23-mediated hypophosphataemic osteomalacia. *Endocrinol Diabetes Metab Case Rep* 2022;2022
<https://doi.org/10.1530/EDM-22-0300>
21. Boots JMM, Quax RAM. High-Dose Intravenous Iron with Either Ferric Carboxymaltose or Ferric Derisomaltose: A Benefit-Risk Assessment. *Drug Saf* 2022;45(10):1019-1036.
<https://doi.org/10.1007/s40264-022-01216-w>
22. Ferric carboxymaltose (Ferrinject) risk of symptomatic hypophosphatemia leading to osteomalacia and fractures. Medicines and Healthcare products Regulatory Agency. November 2020. <https://www.gov.uk/drug-safety-update/ferric-carboxymaltose-ferinject-risk-of-symptomatic-hypophosphataemia-leading-to-osteomalacia-and-fractures>. Accessed in January 10th 2024.